

# Step-by-step digitally planned esthetic restoration

Igor Ristić and  
Nikola Vasić  
Serbia

Igor Ristić and  
Nikola Vasilic

**Patient**

Female, 43

**Clinical situation**

loose frontal incisor, bit dislocated over time

**Diagnosis**

vertical root fracture with cast metal post  
and PFM crown on upper left central incisor

**Surgical solution**

NobelActive® NP

**Restorative solution**

Temporary: Temporary Snap Abutment  
and TempShell

Final: NobelProcera® ASC Abutment with  
e.max Ceram veneering and thin feldspatic  
veneers on 12,11, 22 FDI

**Surgery date**

Dec 10 / 2016

**Final prosthetic delivery**

Jun 21 / 2017

**Total treatment time**

6 months

Patient with vertically fractured root of an upper central incisor underwent digital planning and immediate narrow platform implant placement in the fresh extraction socket. Bone graft material together with connective tissue graft was used to achieve optimal result.

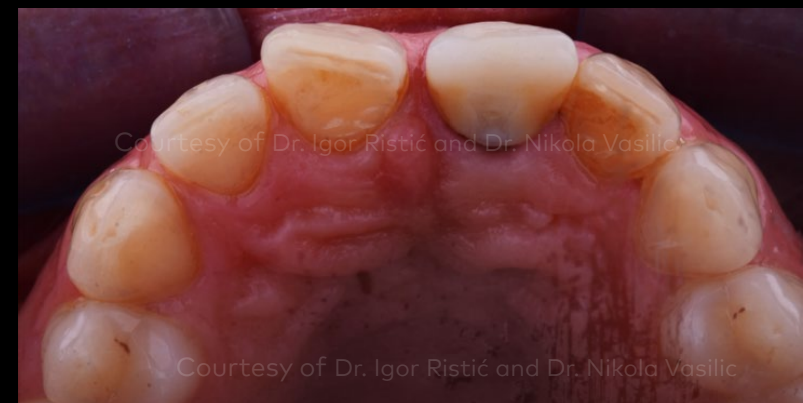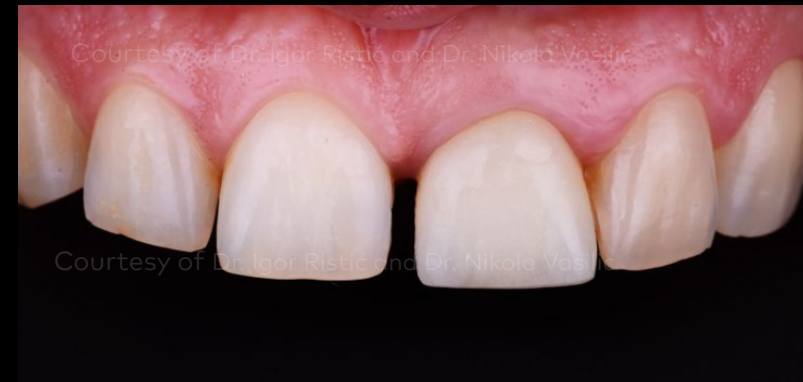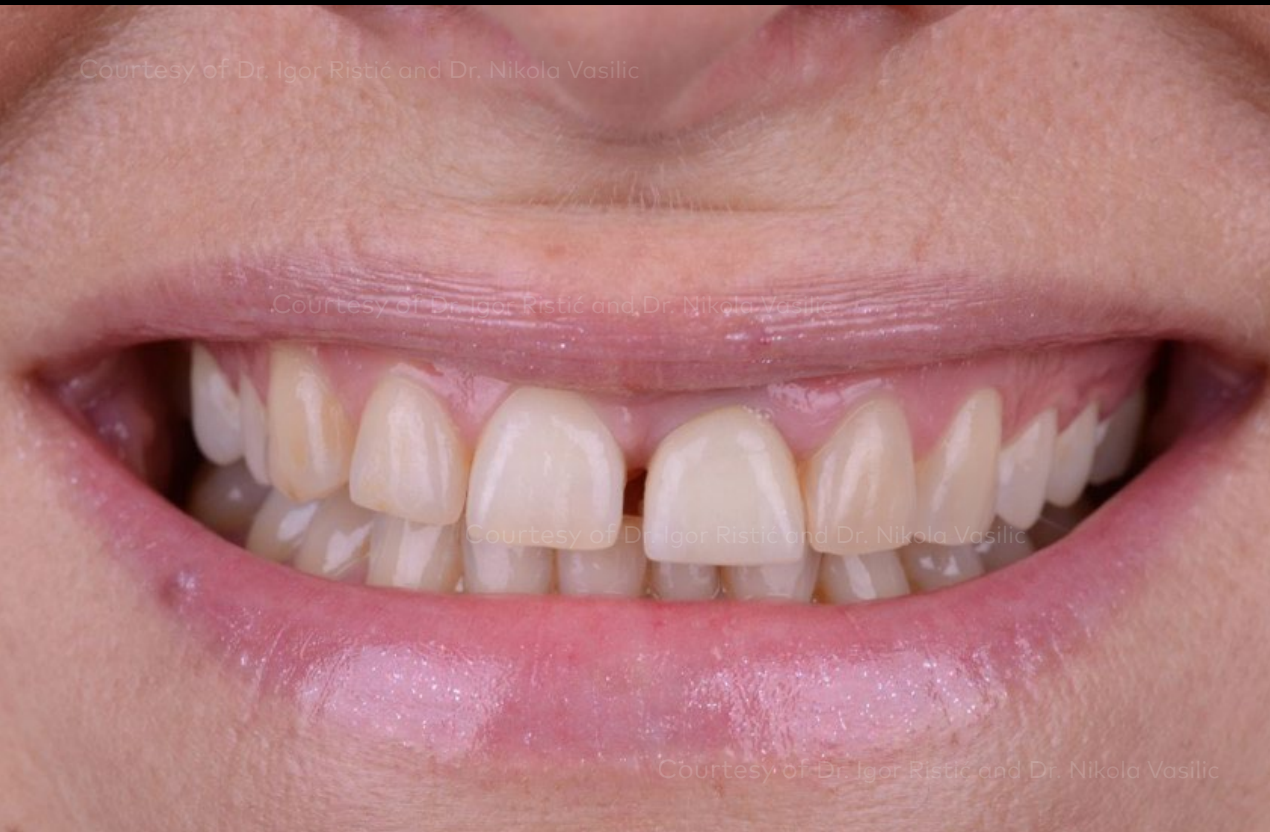## Initial clinical situation

## Treatment planning

## Surgical procedure

## Restorative procedure

## Outcome



Visible dislocation of upper left central incisor, creating esthetic and functional problems

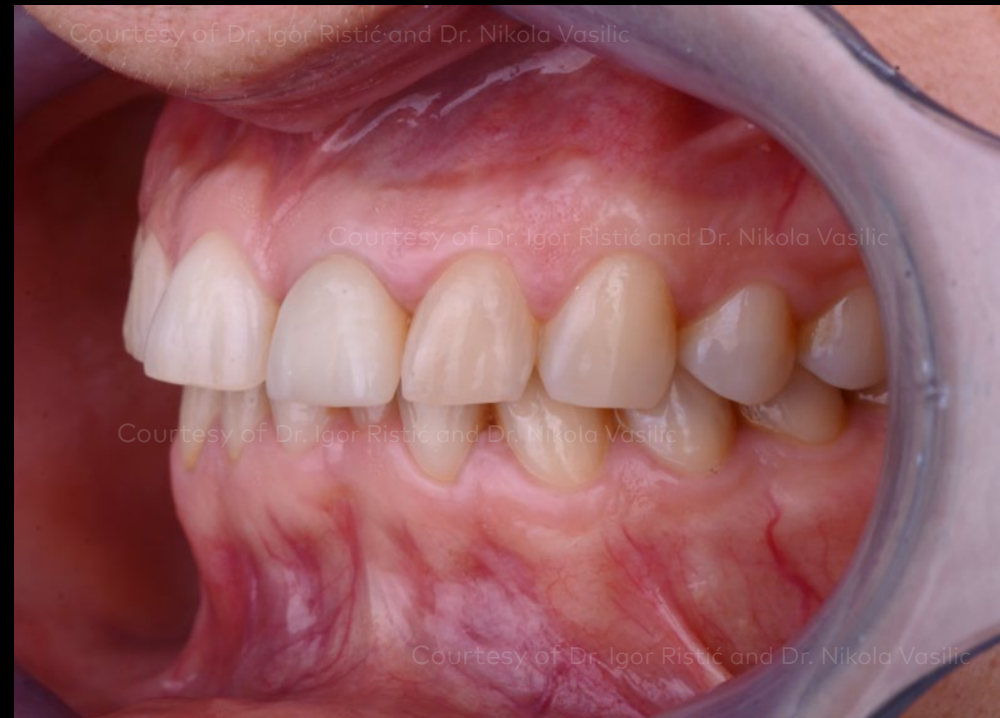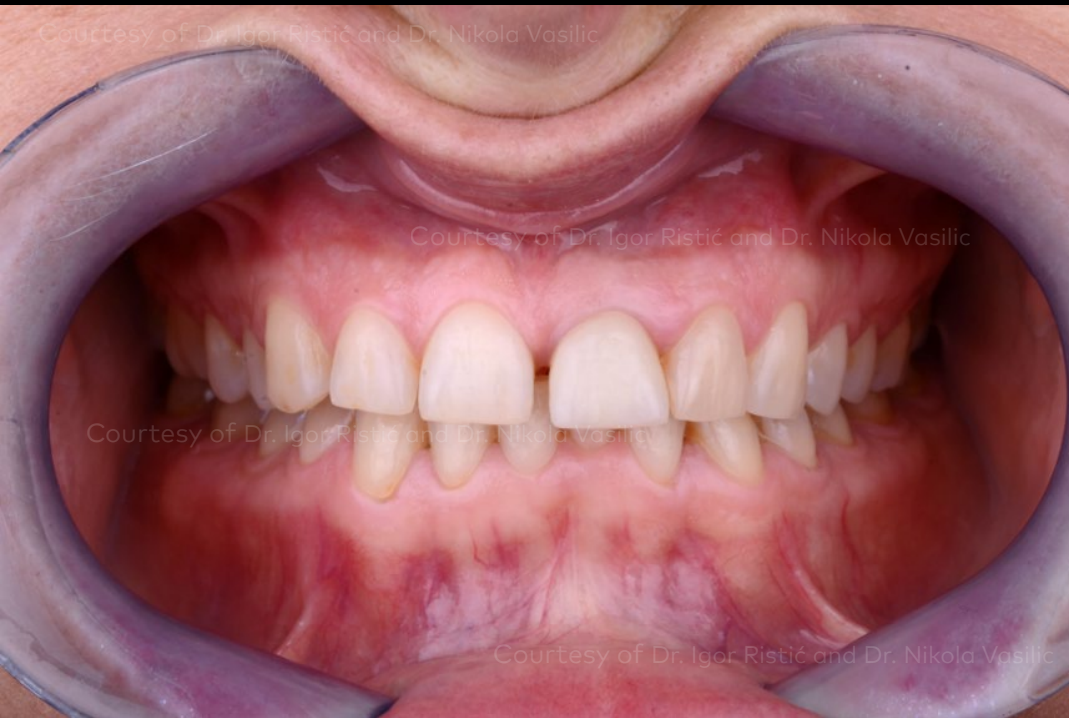**Initial clinical situation**

**Treatment planning**

**Surgical procedure**

**Restorative procedure**

**Outcome**



Intraoral pre-treatment situation

Intraoral pre-treatment situation - lateral view



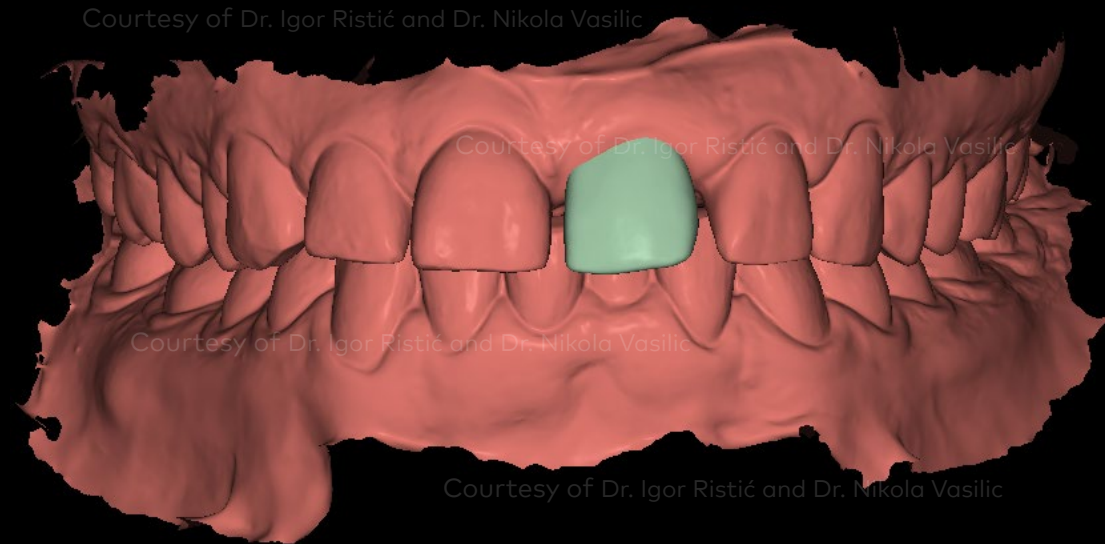
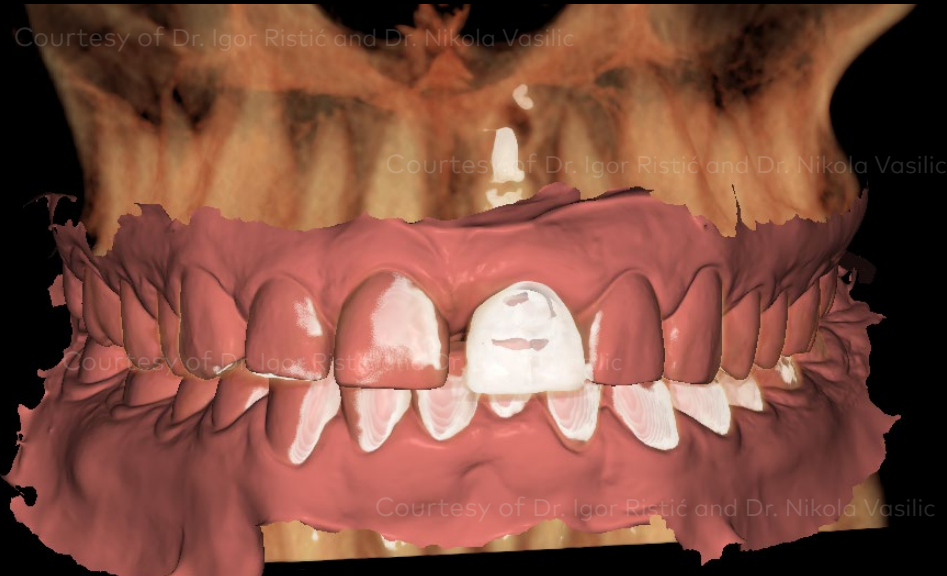## Initial clinical situation

## Treatment planning

## Surgical procedure

## Restorative procedure

## Outcome



SmartFusion of a (CB)CT scan and intraoral scans in NobelClinician® software

SmartSetup – a digital wax-up proposed by the software of upper left central incisor in NobelClinician® software

# Initial clinical situation

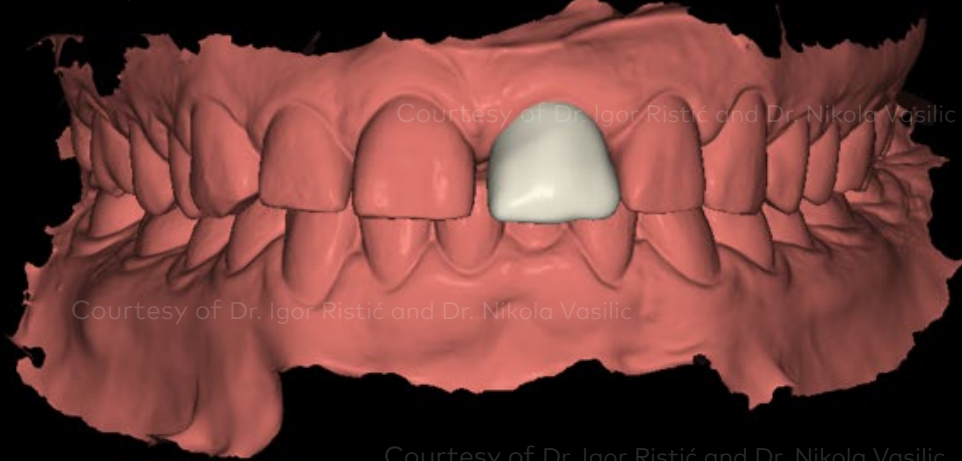
# Treatment planning

# Surgical procedure

# Restorative procedure

# Outcome

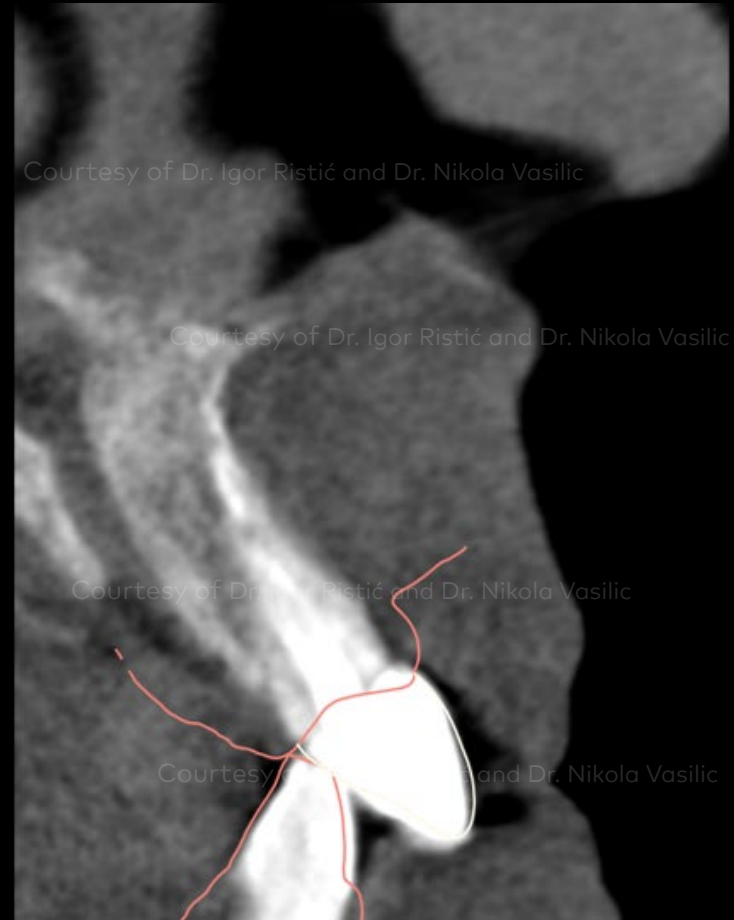
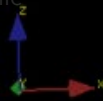
Courtesy of Dr. Igor Ristić and Dr. Nikola Vasilic



Courtesy of Dr. Igor Ristić and Dr. Nikola Vasilic

Courtesy of Dr. Igor Ristić and Dr. Nikola Vasilic

Courtesy of Dr. Igor Ristić and Dr. Nikola Vasilic



Courtesy of Dr. Igor Ristić and Dr. Nikola Vasilic

Courtesy of Dr. Igor Ristić and Dr. Nikola Vasilic

Courtesy of Dr. Igor Ristić and Dr. Nikola Vasilic

Courtesy of Dr. Igor Ristić and Dr. Nikola Vasilic

Analysis of sagittal aspect of tooth, soft tissues and bone

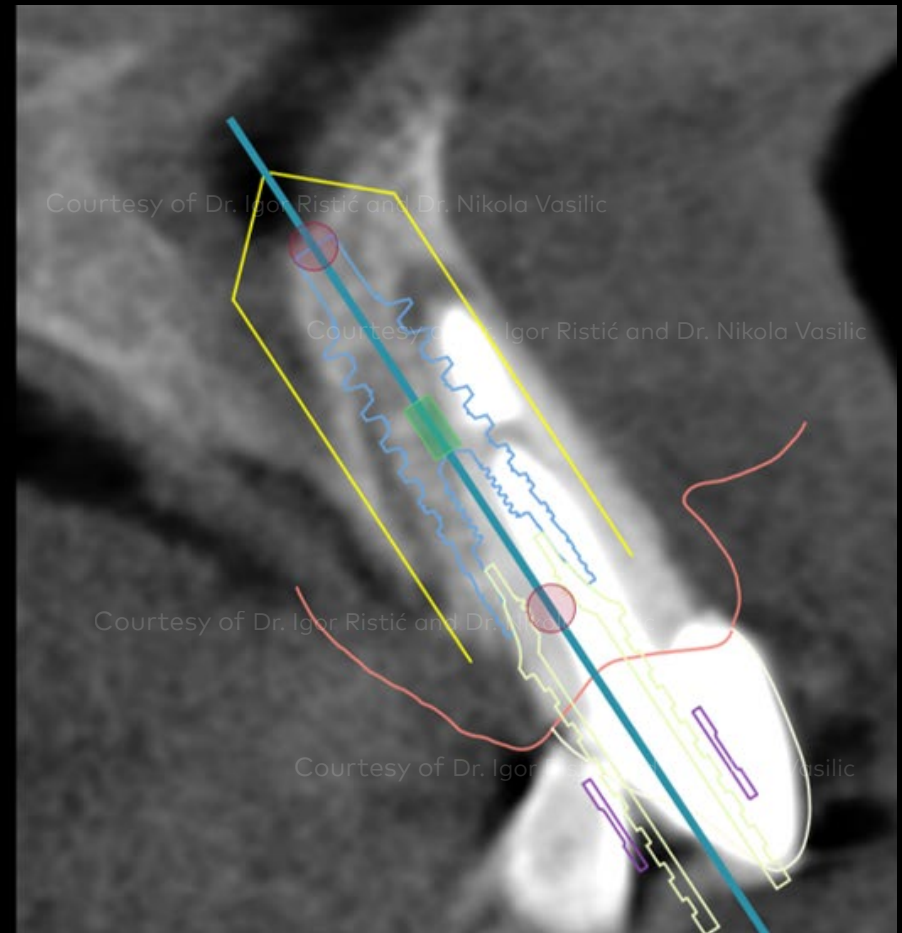
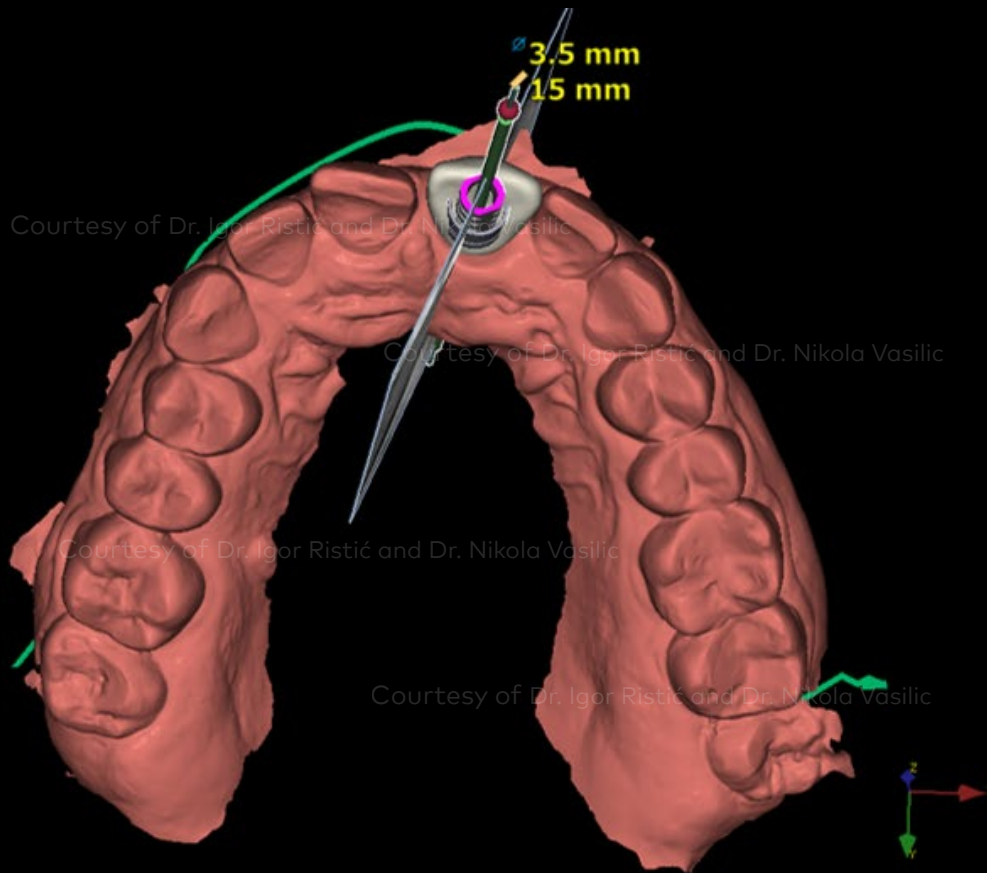
# Initial clinical situation

# Treatment planning

# Surgical procedure

# Restorative procedure

# Outcome



Digital position of implant in planning phase, Temporary Snap Abutment included



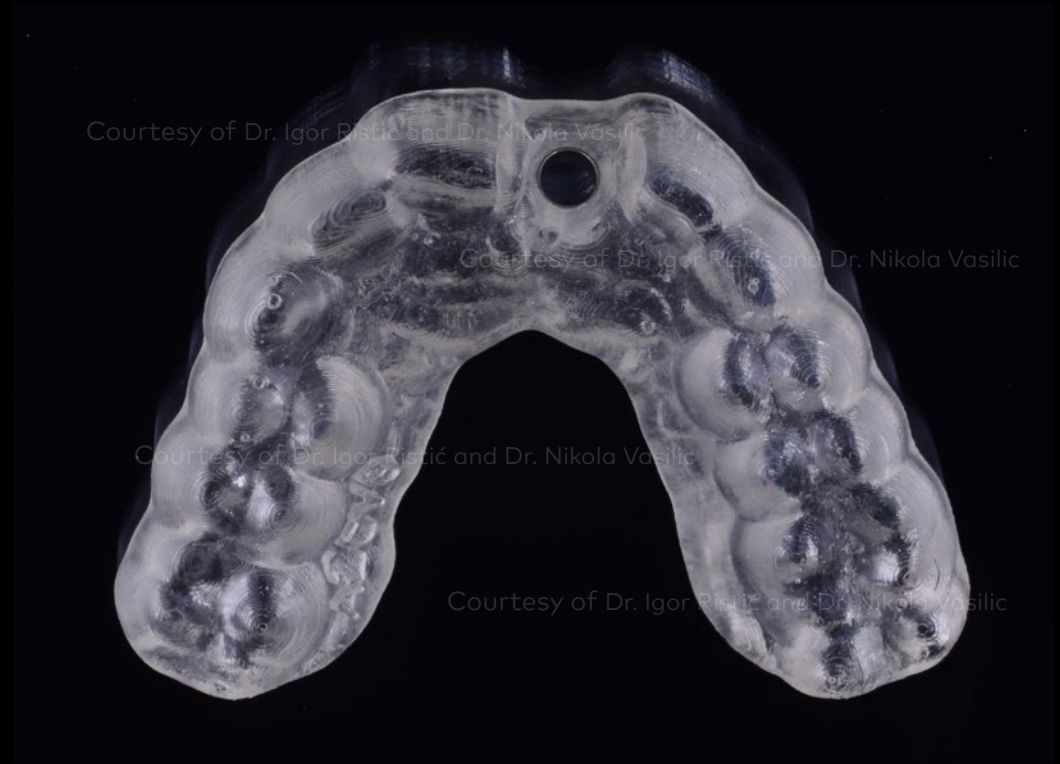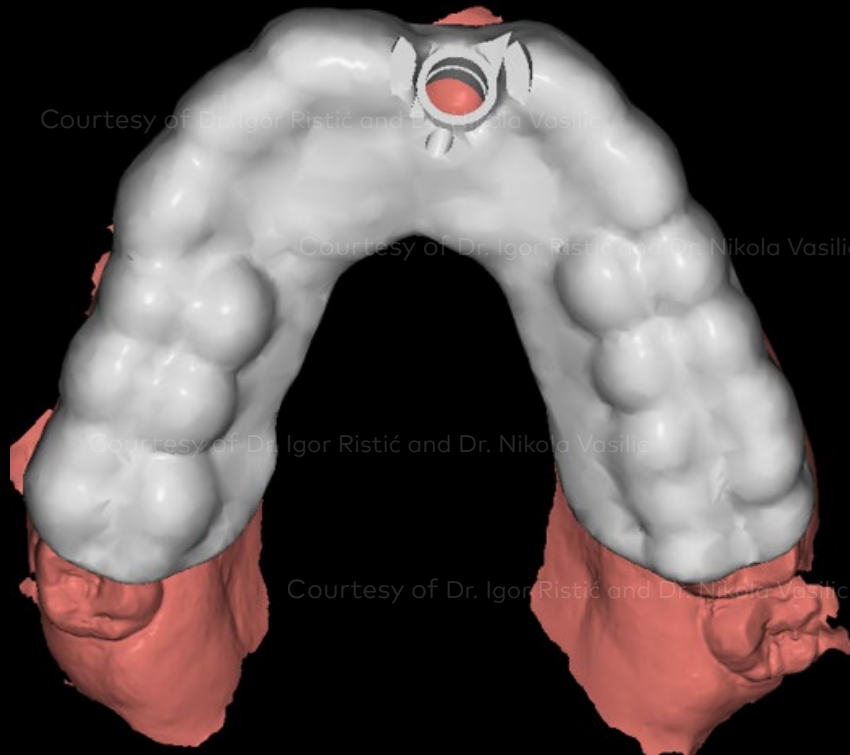
**Initial clinical situation**

**Treatment planning**

**Surgical procedure**

**Restorative procedure**

**Outcome**



Digital design of surgical template in NobelClinician® software

Printed NobelGuide® template ready for surgical procedure

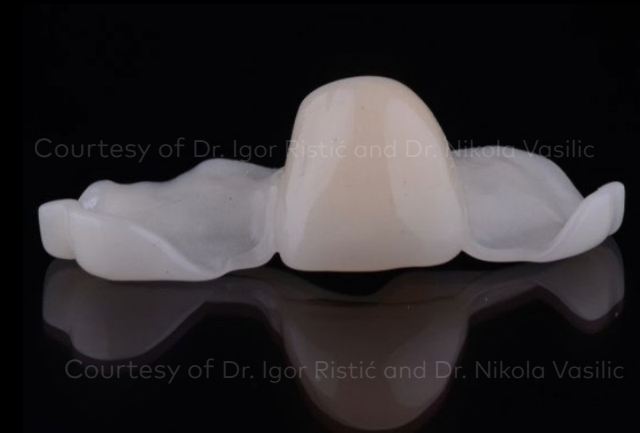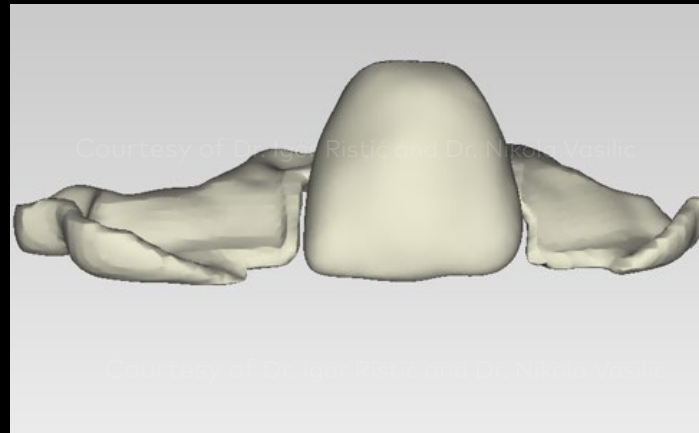
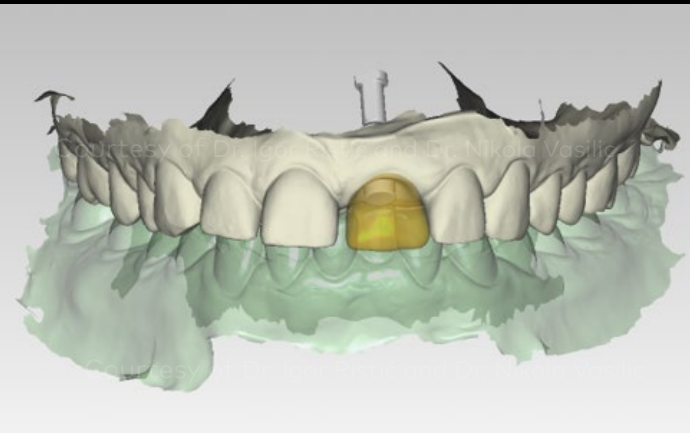
## Initial clinical situation

## Treatment planning

## Surgical procedure

## Restorative procedure

## Outcome



Digitally designed TempShell in DTX Studio™ design software

TempShell milled in local dental laboratory, made from PMMA

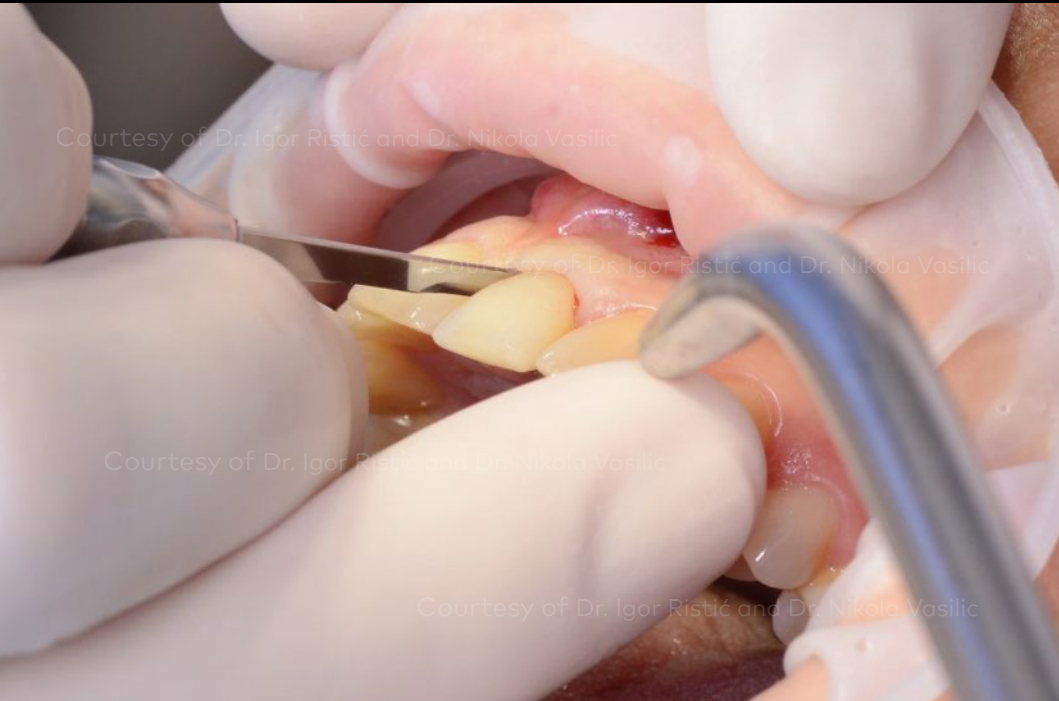## Initial clinical situation

## Treatment planning

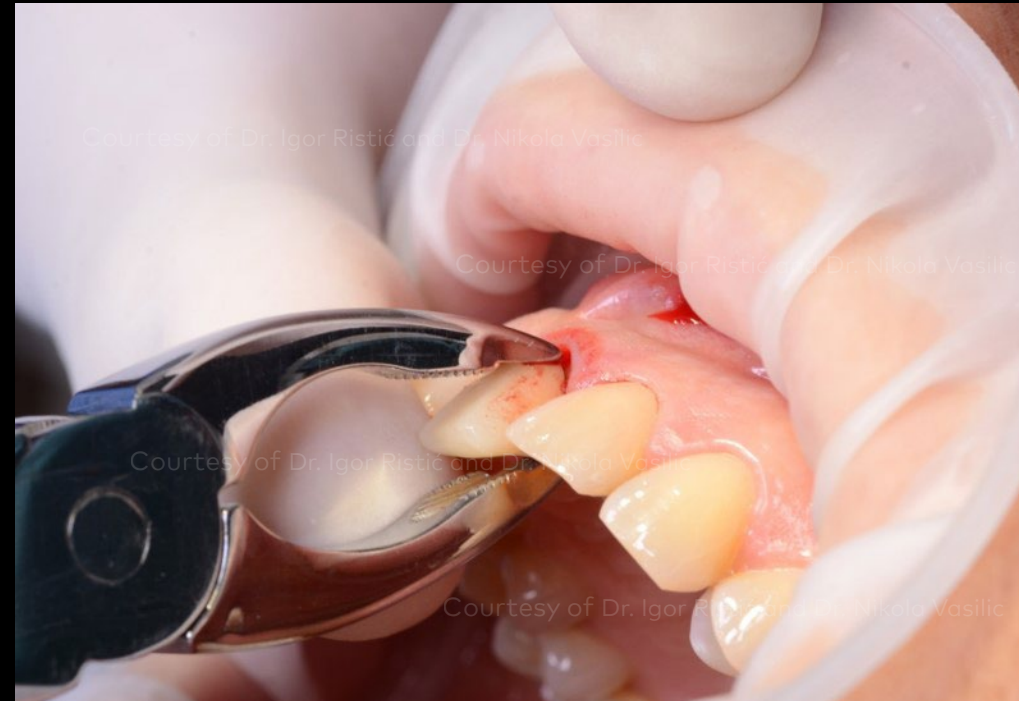## Surgical procedure

## Restorative procedure

## Outcome



Intrasulcular incision



Forceps adapted to the crown for efficient luxation of the tooth

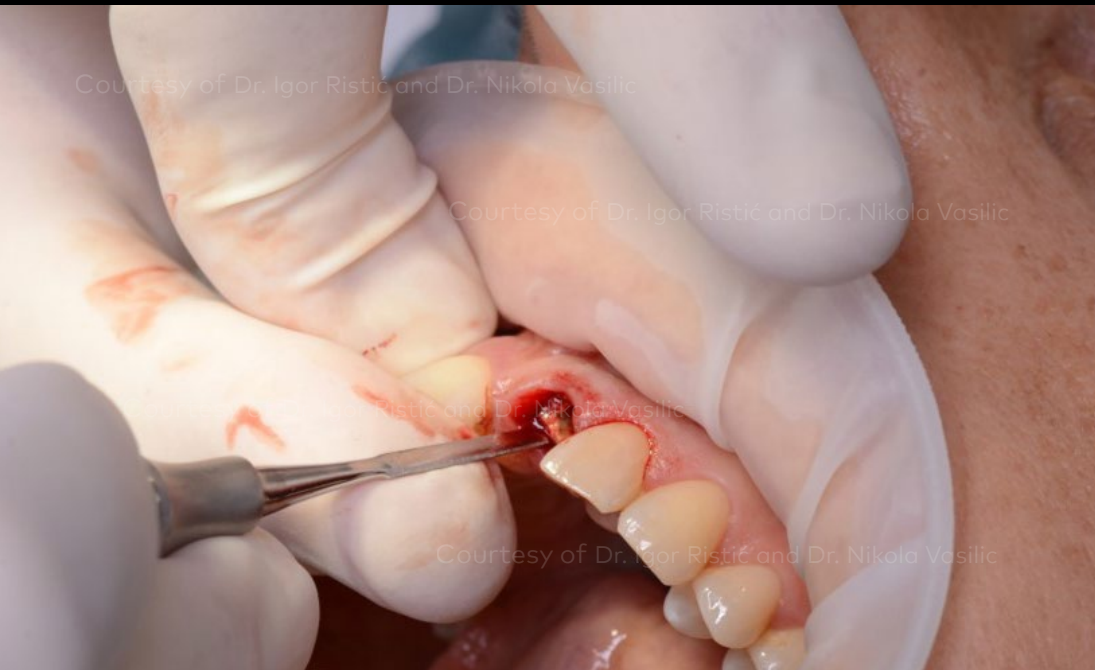## Initial clinical situation

## Treatment planning

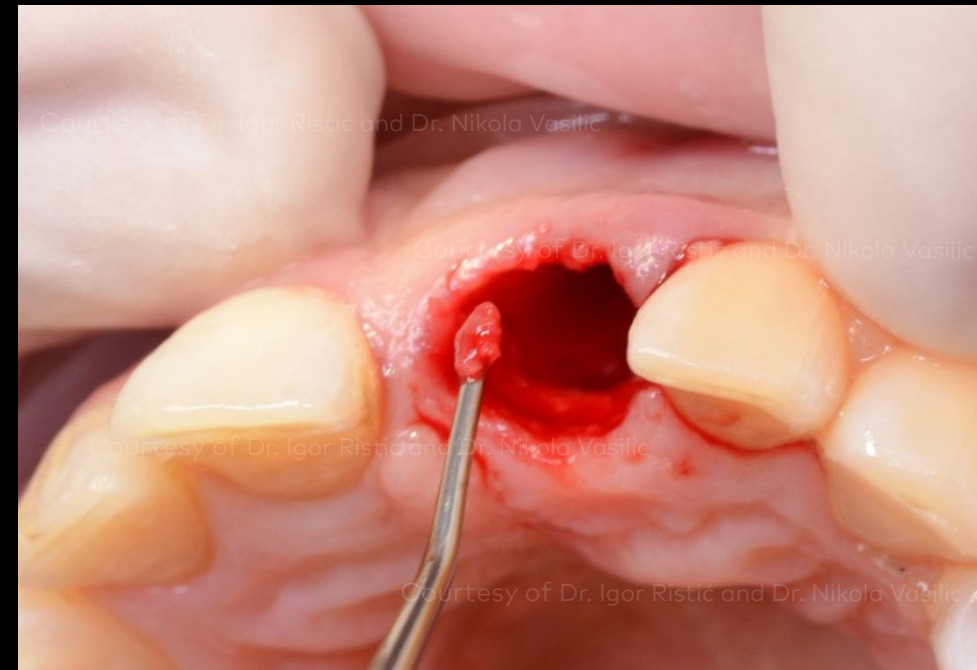
## Surgical procedure

## Restorative procedure

## Outcome



Atraumatic removal of the remaining root structures



Cleaning up of the alveolar socket, removing all granulation tissues

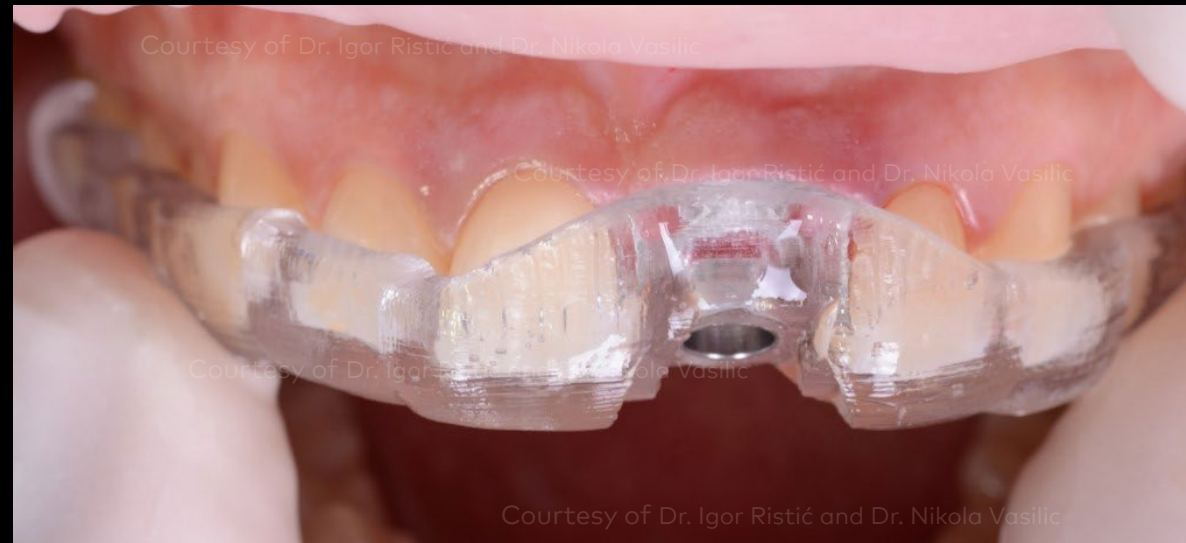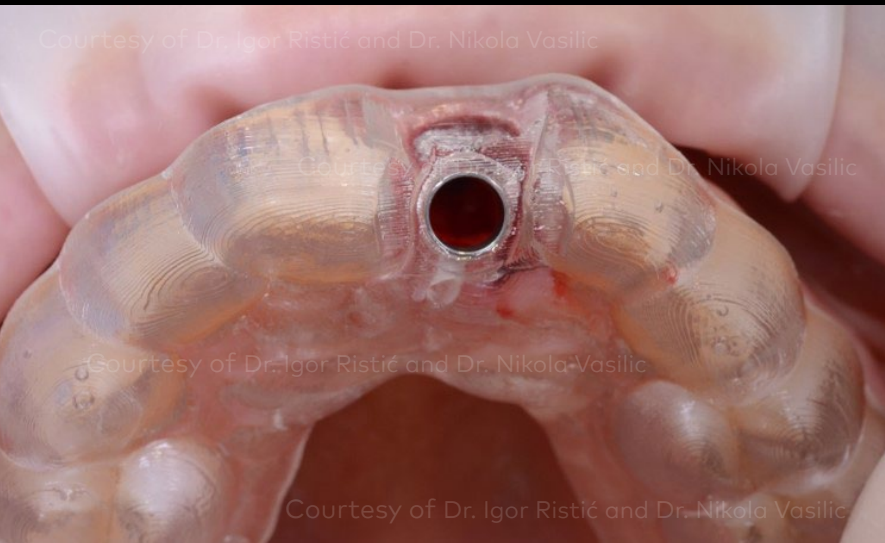**Initial clinical situation**

**Treatment planning**

**Surgical procedure**

**Restorative procedure**

**Outcome**



Try-in of the surgical template intraorally – occlusal view

Try-in of the surgical template intraorally – frontal view

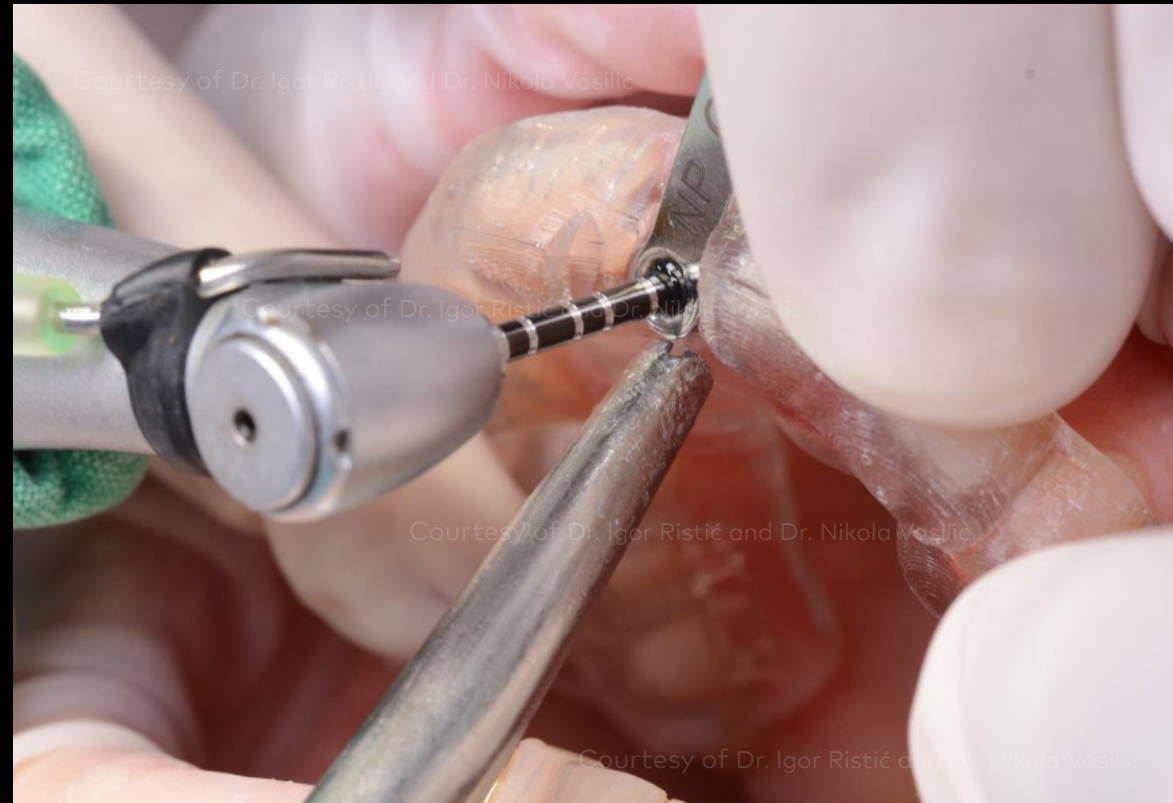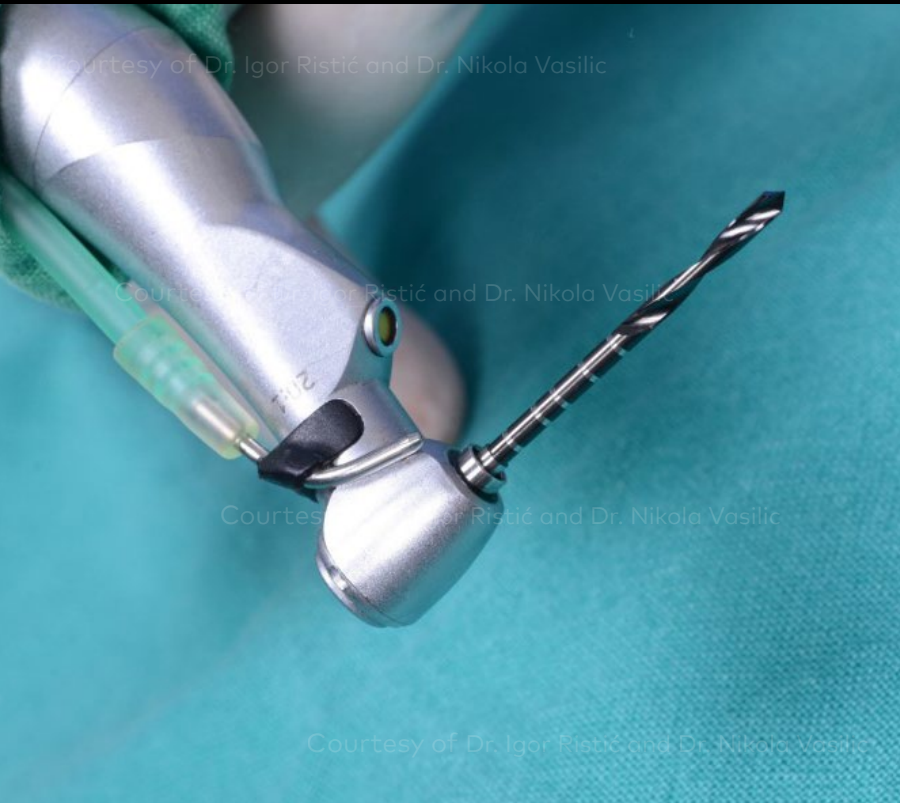## Initial clinical situation

## Treatment planning

## Surgical procedure

## Restorative procedure

## Outcome



Guided Twist Drill (10+) 7-13 mm, Ø 2 mm

Initial drilling using Guided Twist Drill\*

\* As this was a case with immediate implant placement in an extraction site, the Screw Tap was not used, due to the size of the alveolar socket

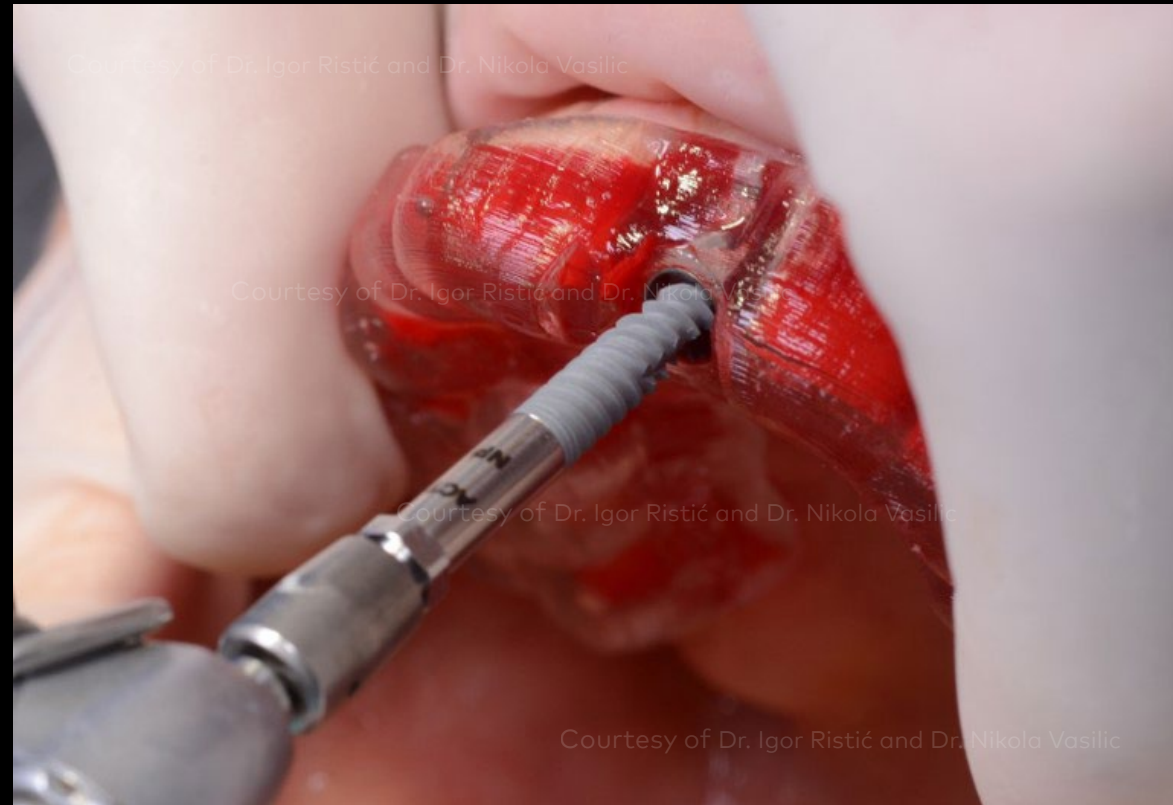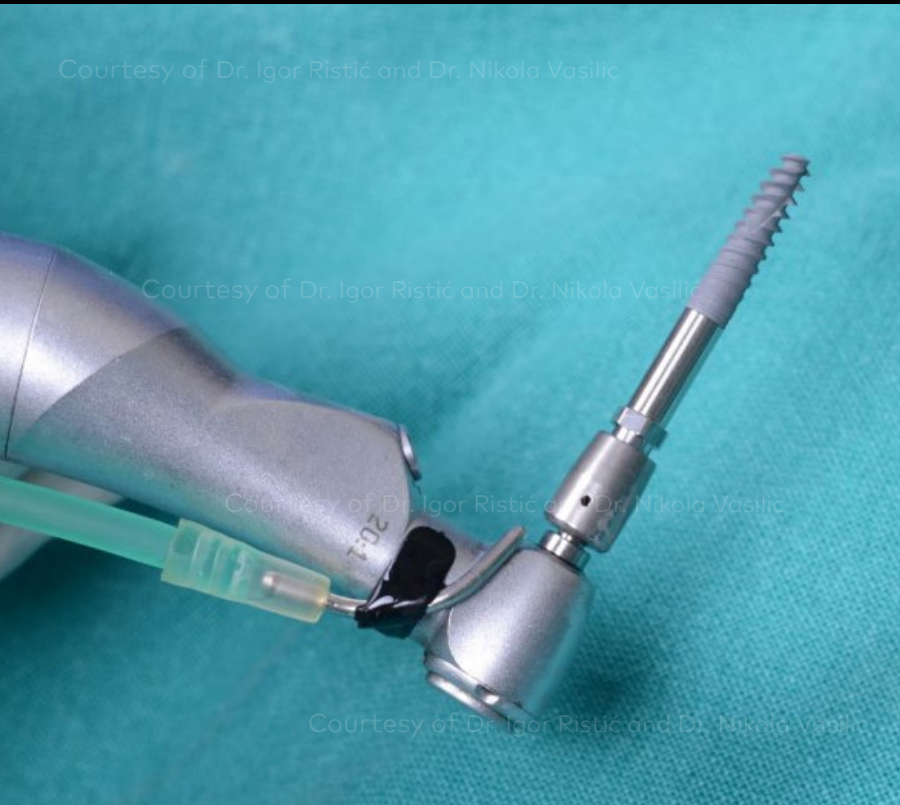# Initial clinical situation

# Treatment planning

# Surgical procedure

# Restorative procedure

# Outcome



NobelActive® NP 15mm

Implant insertion using the NobelGuide® surgical template

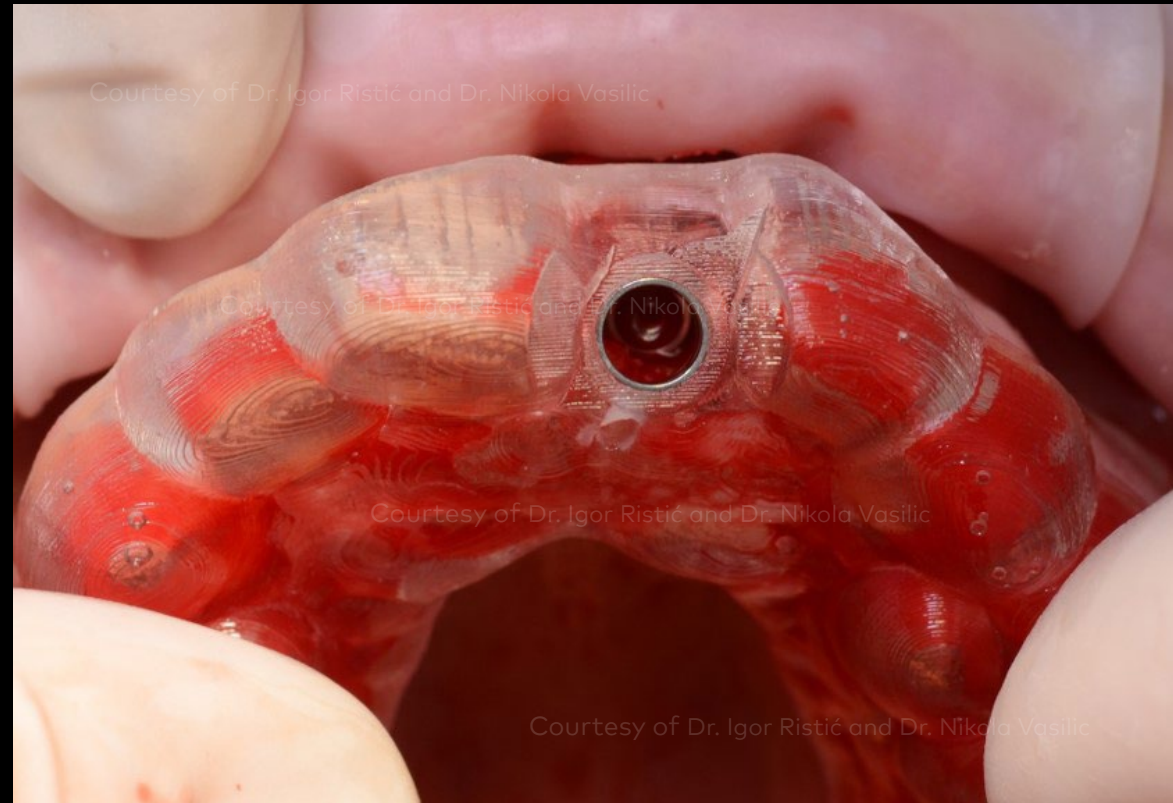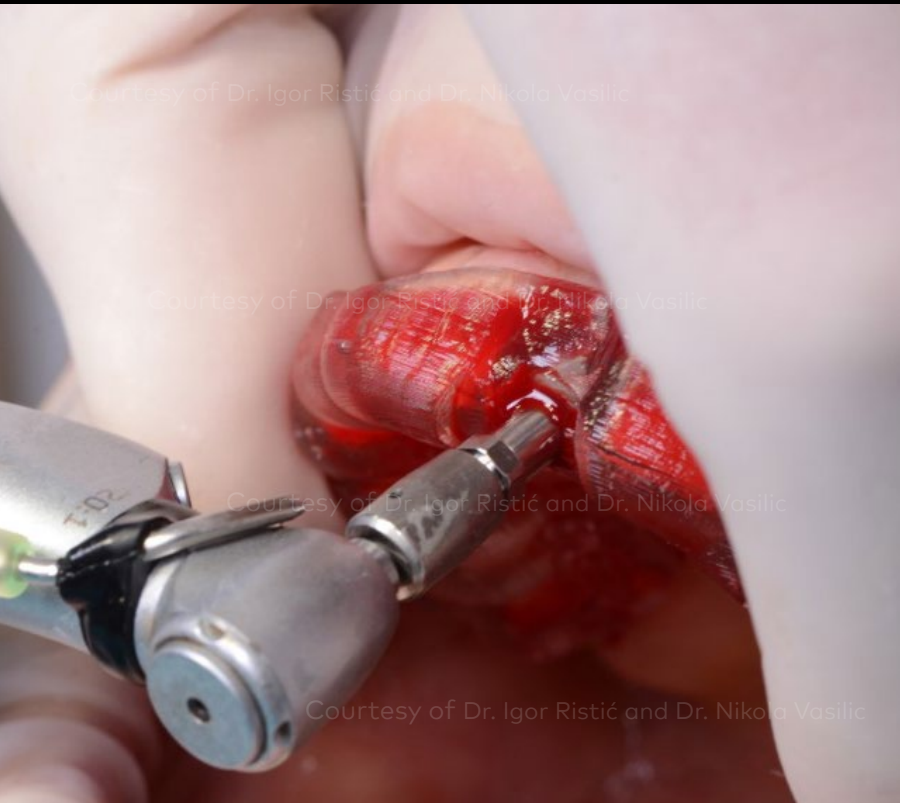**Initial clinical situation**

**Treatment planning**

**Surgical procedure**

**Restorative procedure**

**Outcome**



Final implant positioning

Verification of implant position according to the surgical template



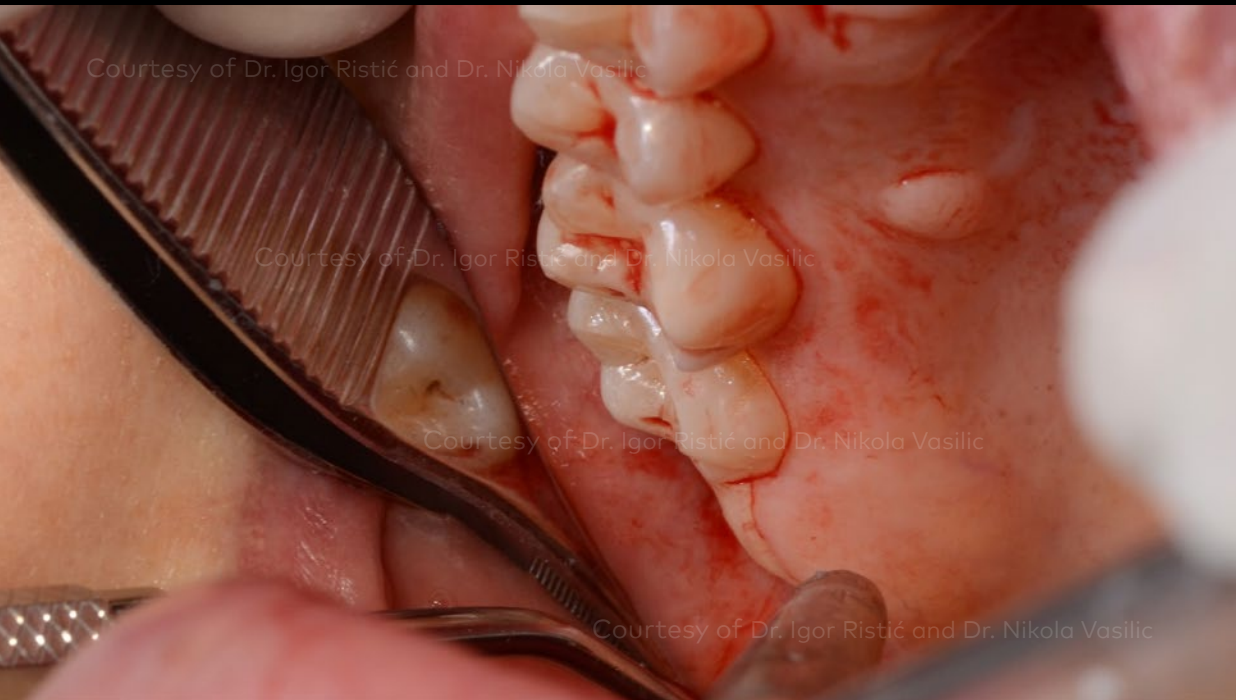## Initial clinical situation

## Treatment planning

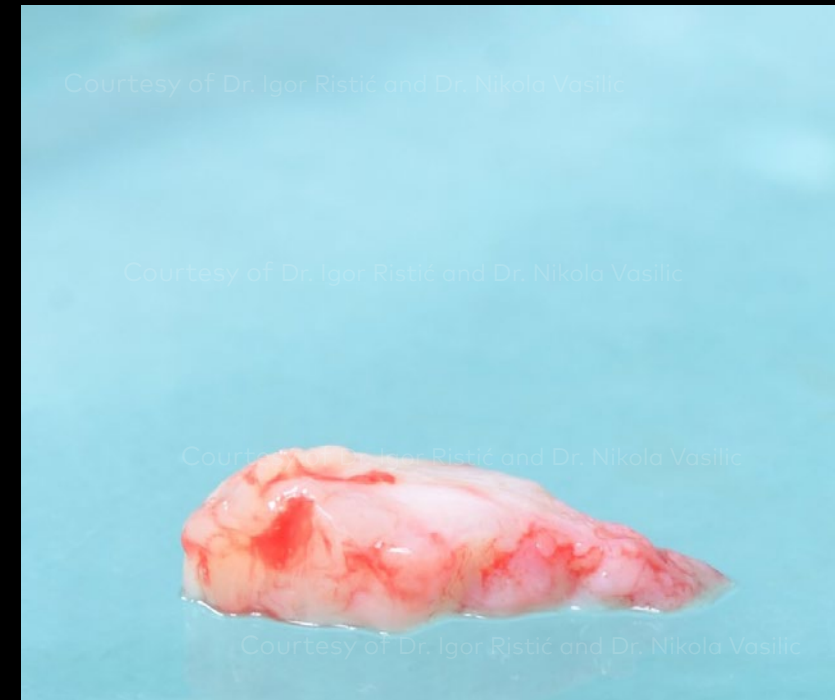## Surgical procedure

## Restorative procedure

## Outcome



Harvesting of the connective tissue graft from tuberosity



Connective tissue graft

Initial clinical situation

Treatment planning

Surgical procedure

Restorative procedure

Outcome



creos™ xenogain bovine bone mineral matrix, S (0.2-1.0 mm)

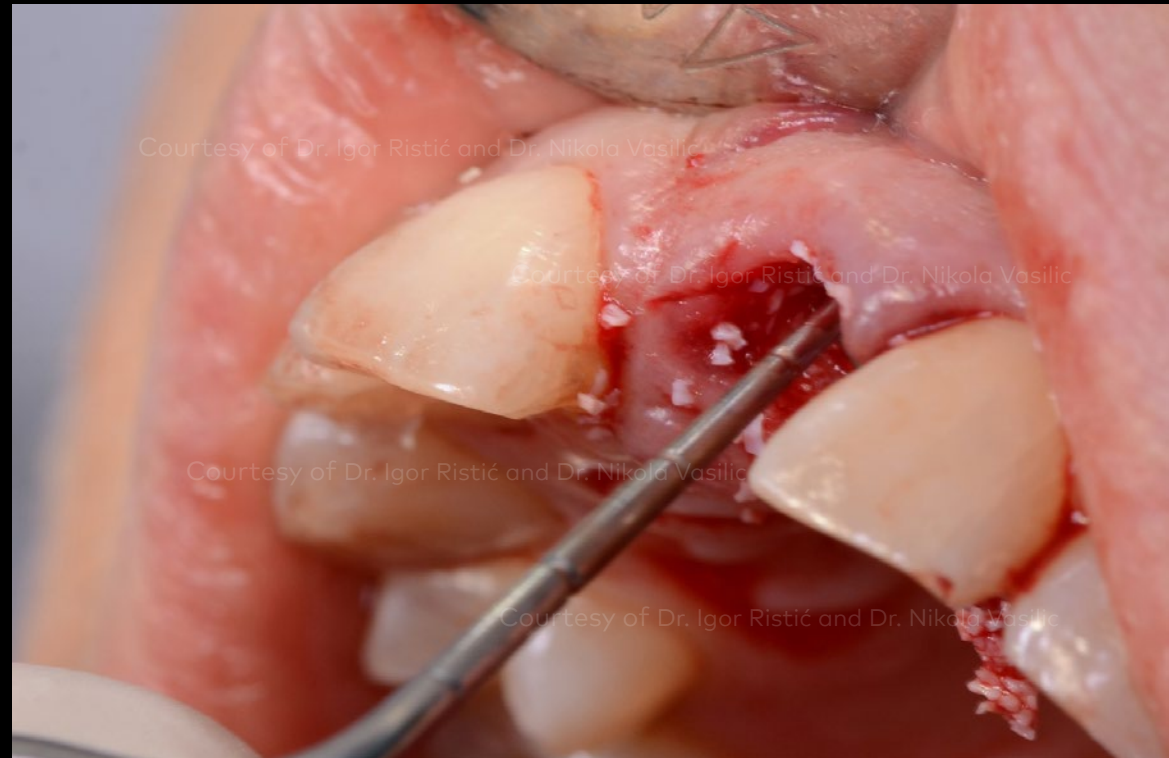
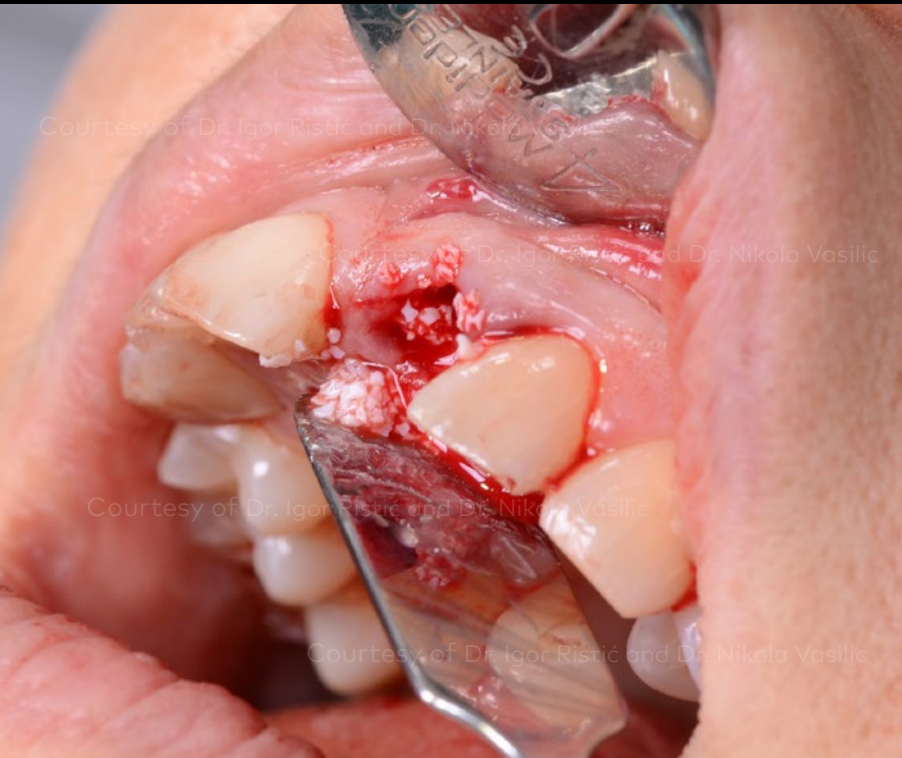## Initial clinical situation

## Treatment planning

## Surgical procedure

## Restorative procedure

## Outcome



creos™ xenogain material is being placed into the gap between the implant and buccal wall of the extraction socket.

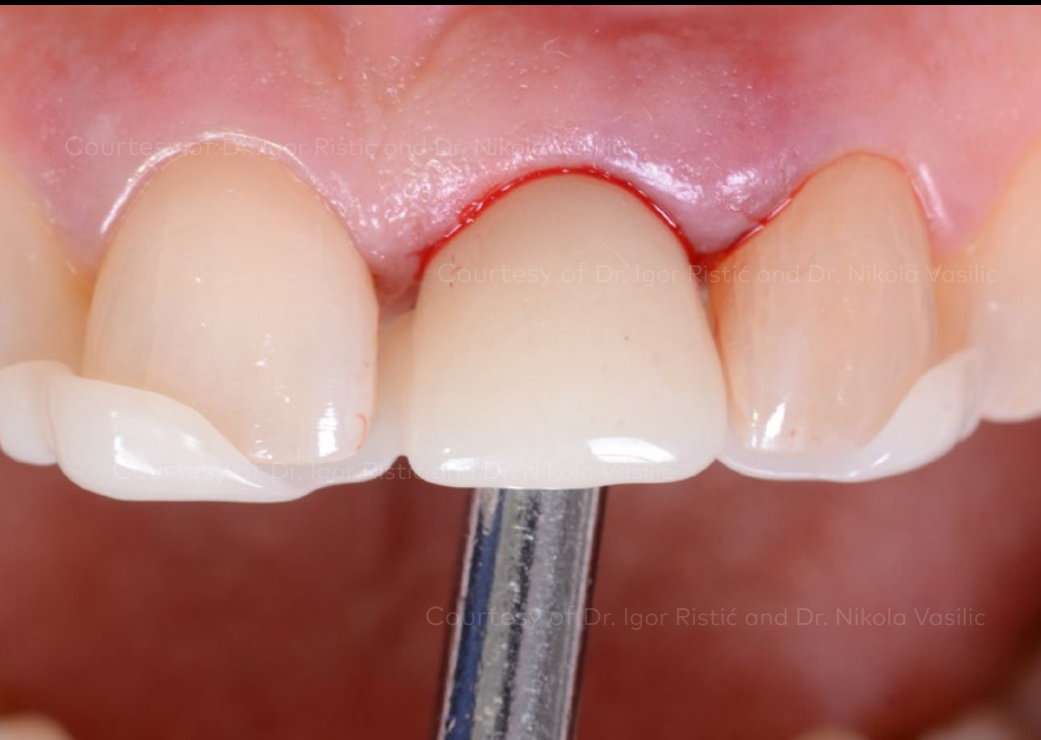**Initial clinical situation**

**Treatment planning**

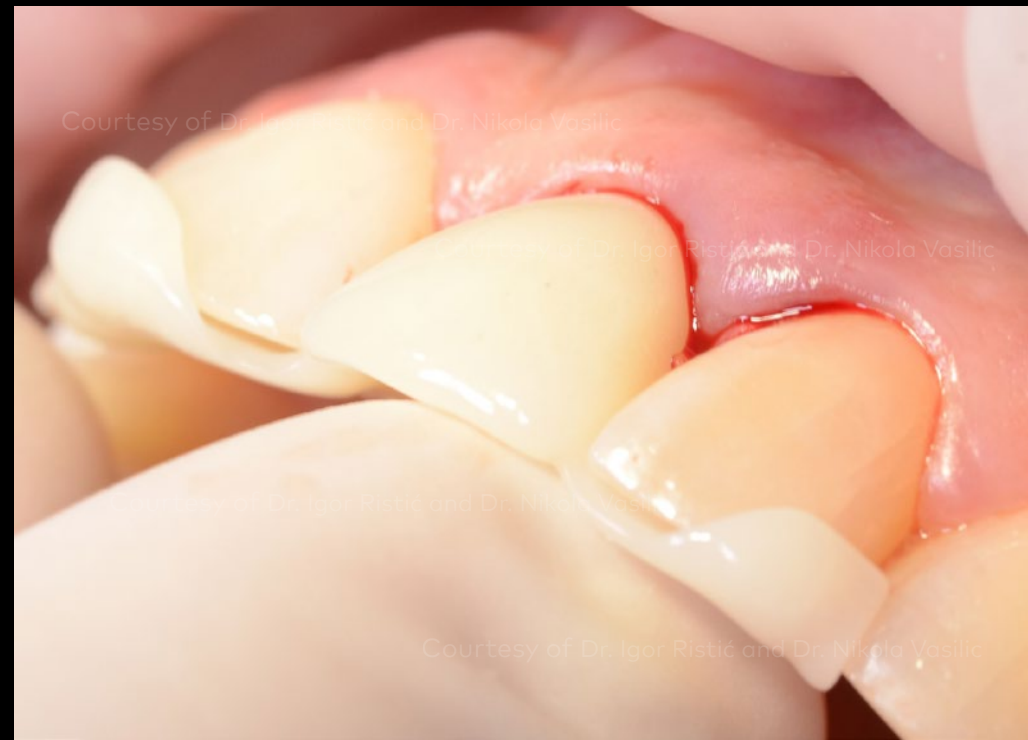**Surgical procedure**

**Restorative procedure**

**Outcome**



Try-in of the TempShell – vestibular view



Try-in of the TempShell – vestibular view

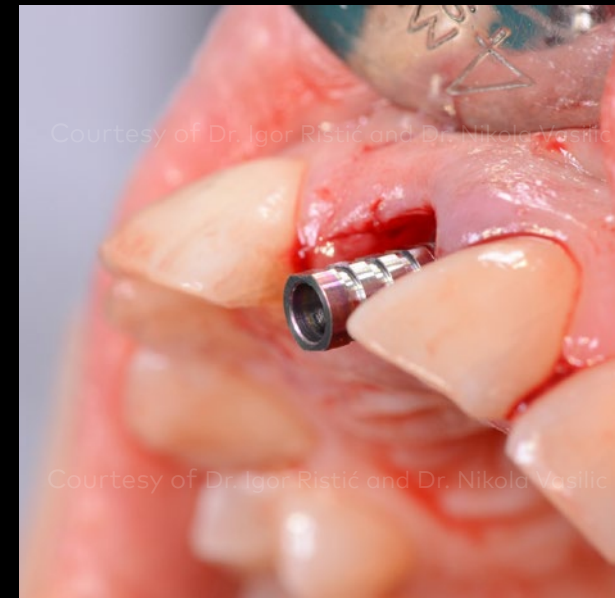
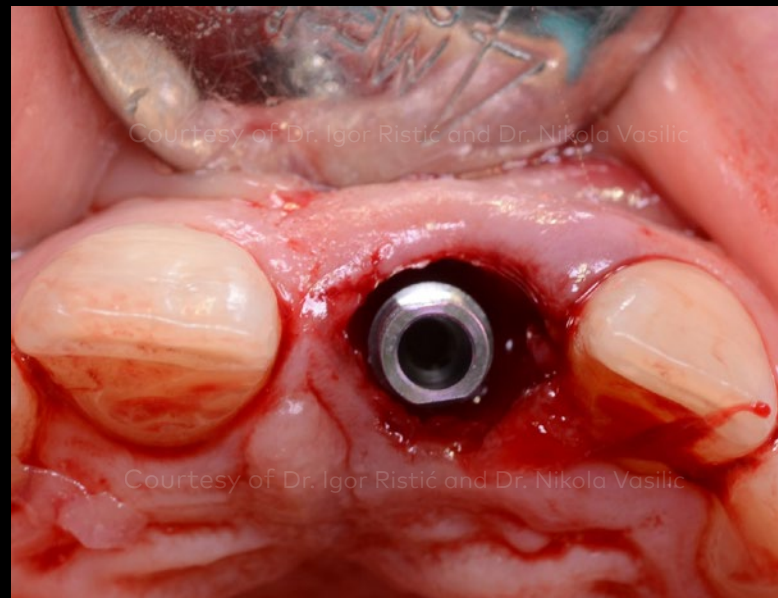
## Initial clinical situation

## Treatment planning

## Surgical procedure

## Restorative procedure

## Outcome



Extraoral picture of the Temporary Snap Abutment

Intraoral pictures after the Temporary Snap Abutment try-in

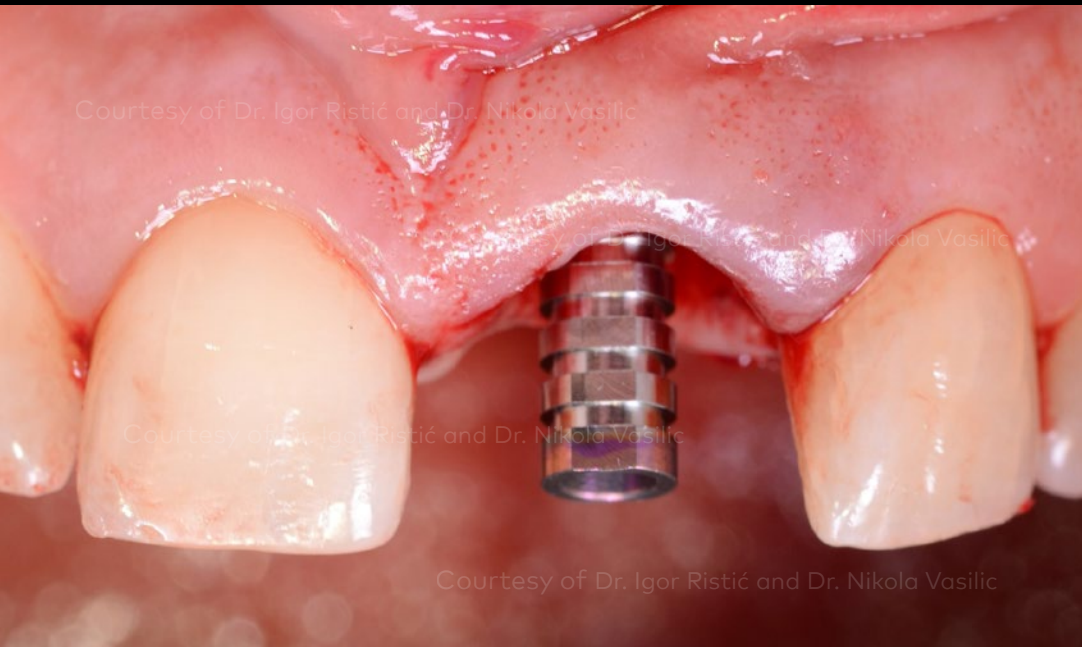**Initial clinical situation**

**Treatment planning**

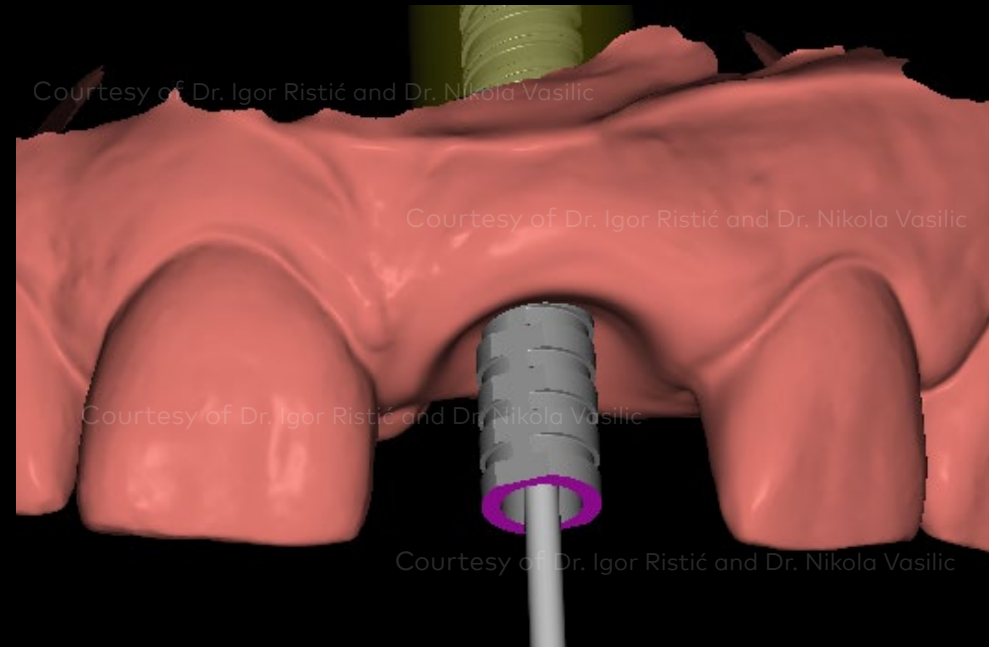
**Surgical procedure**

**Restorative procedure**

**Outcome**



Intraoral position of Temporary Snap Abutment is as previously planned



Planning position of Temporary Snap Abutment

**Initial clinical situation**

**Treatment planning**

**Surgical procedure**

**Restorative procedure**

**Outcome**



Shortening of the Temporary Snap Abutment

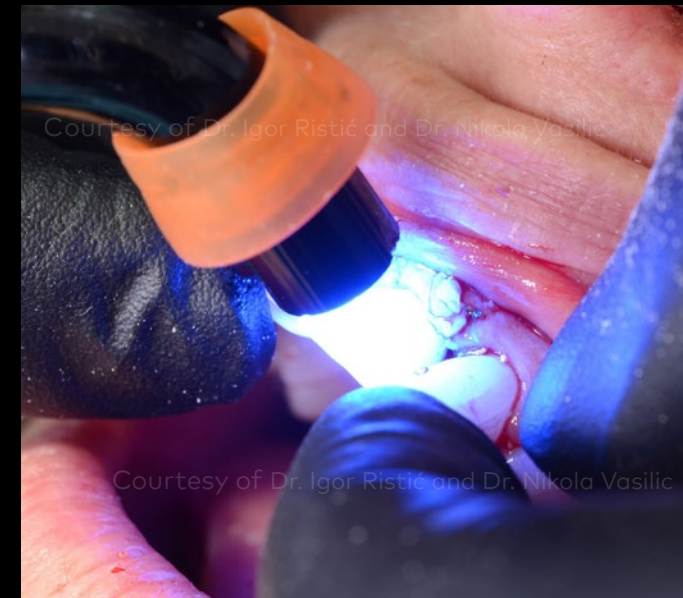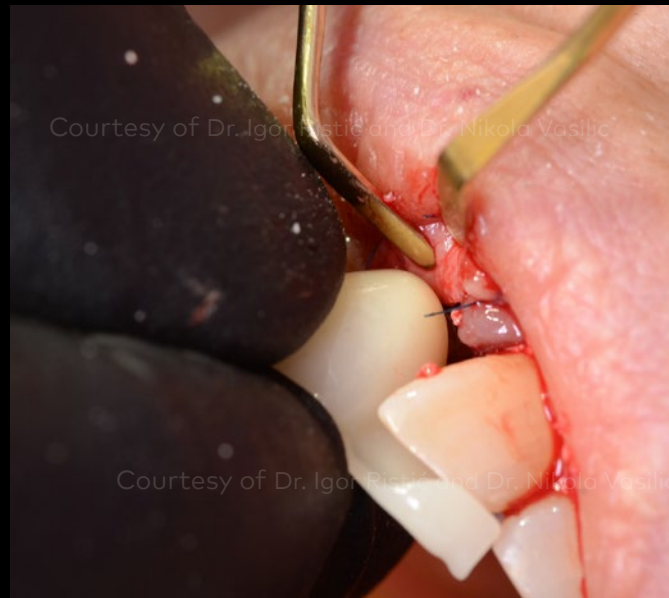## Initial clinical situation

## Treatment planning

## Surgical procedure

## Restorative procedure

## Outcome



Loading of light cure material for TempShell relining

Positioning of the TempShell

Light curing and setting in place of TempShell on the Temporary Snap Abutment



## Initial clinical situation

## Treatment planning

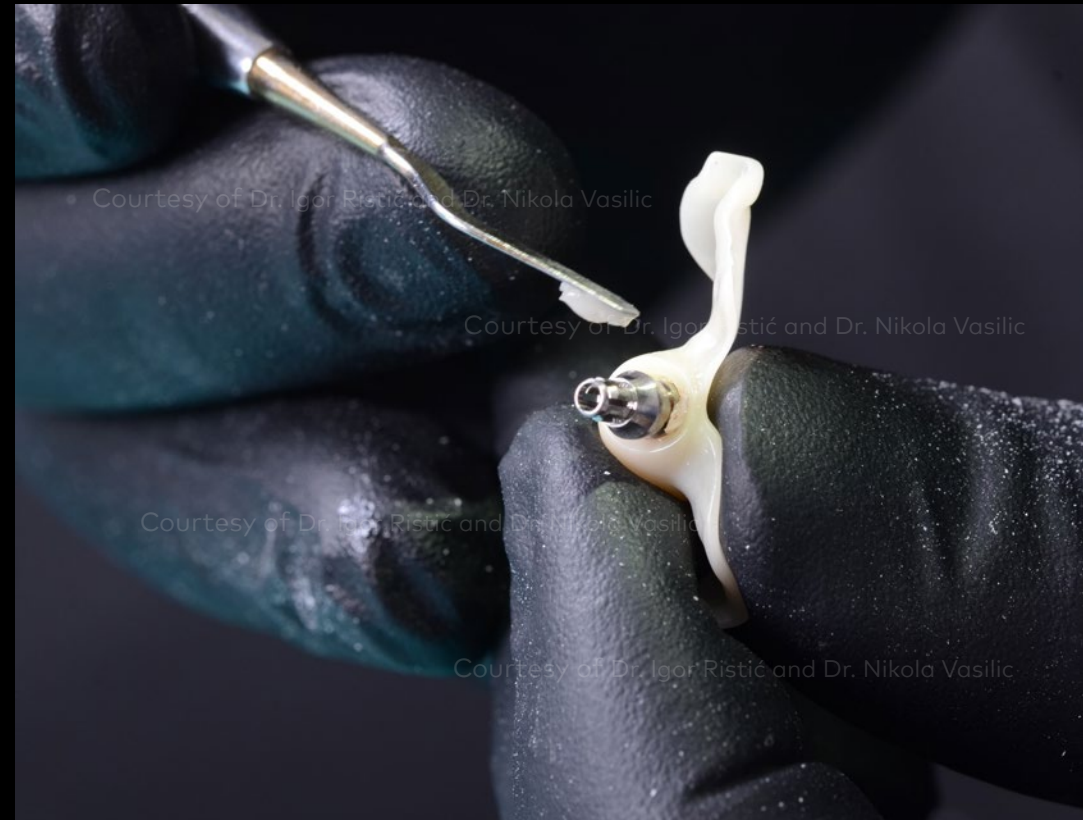## Surgical procedure

## Restorative procedure

## Outcome



Temporary Snap Abutment in TempShell after polymerization in right position



Extraoral final contouring of emergence profile on temporary crown

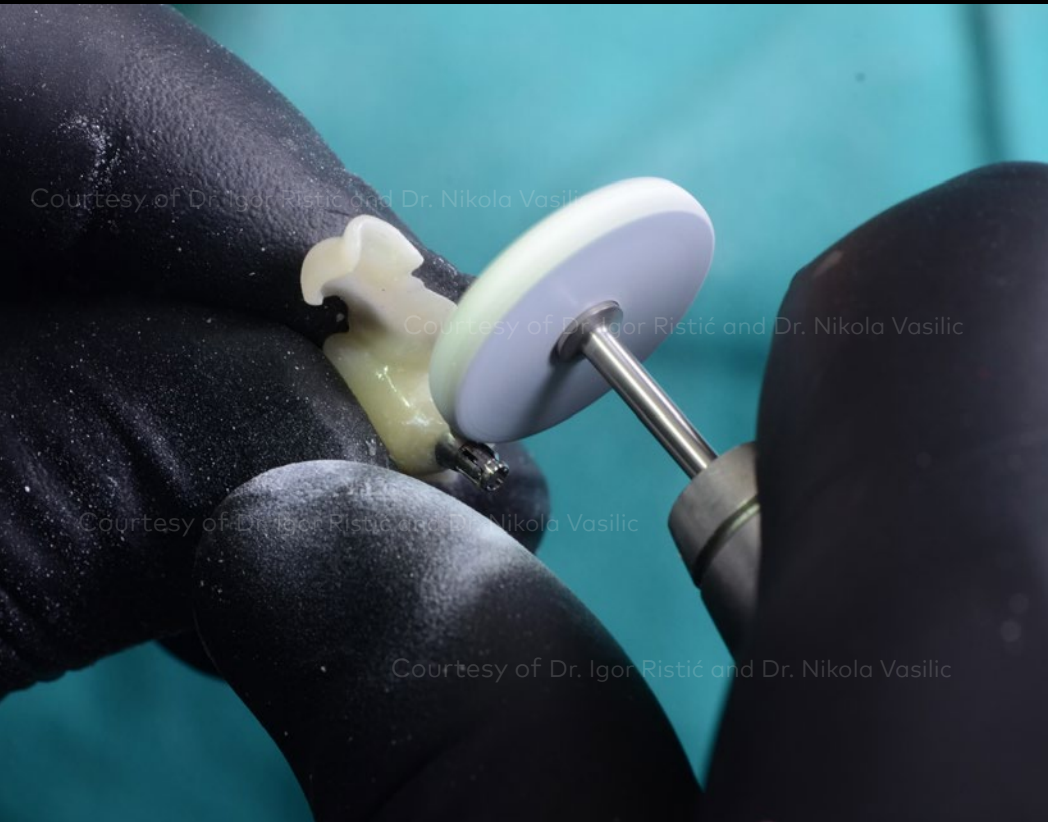## Initial clinical situation

## Treatment planning

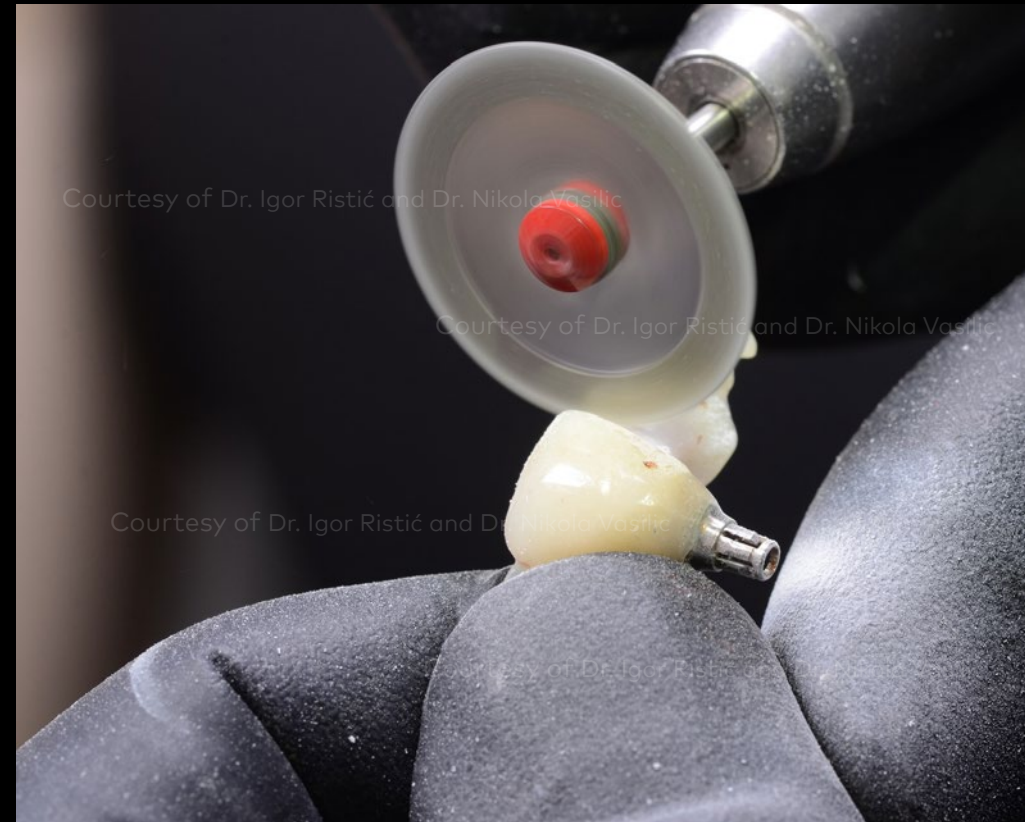## Surgical procedure

## Restorative procedure

## Outcome



Finishing and polishing of emergence profile



Removing wings for final placement of TempShell

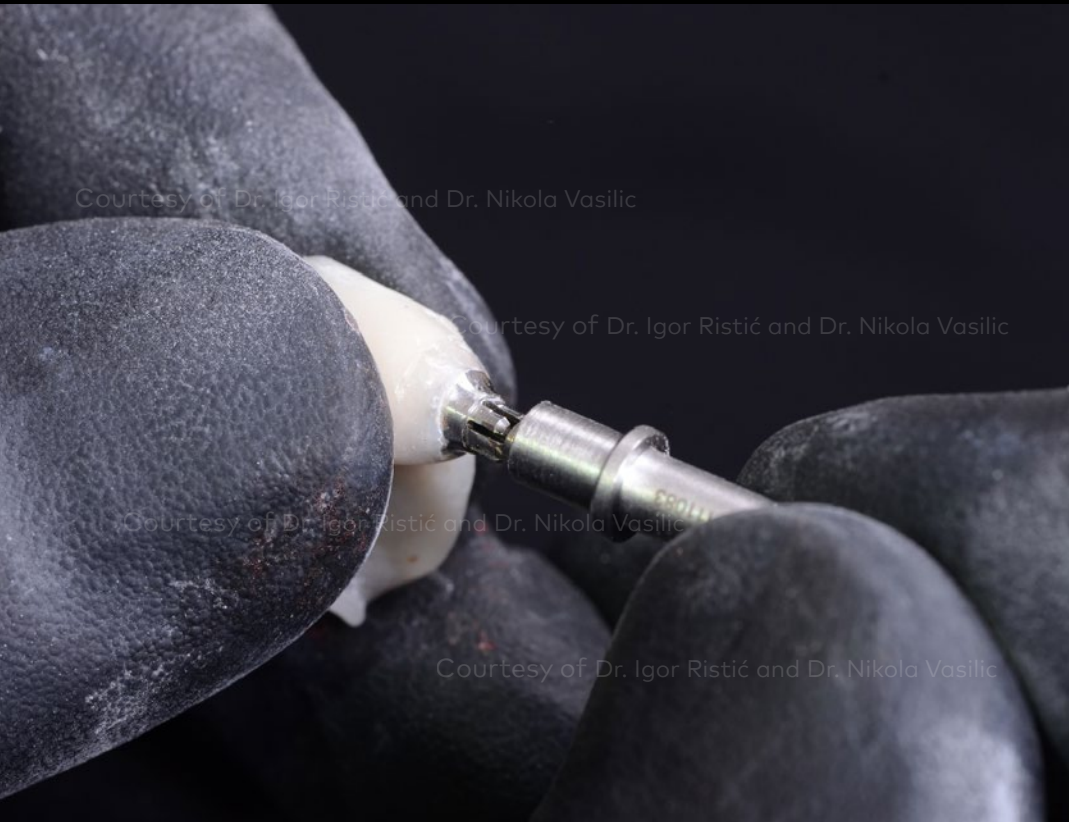## Initial clinical situation

## Treatment planning

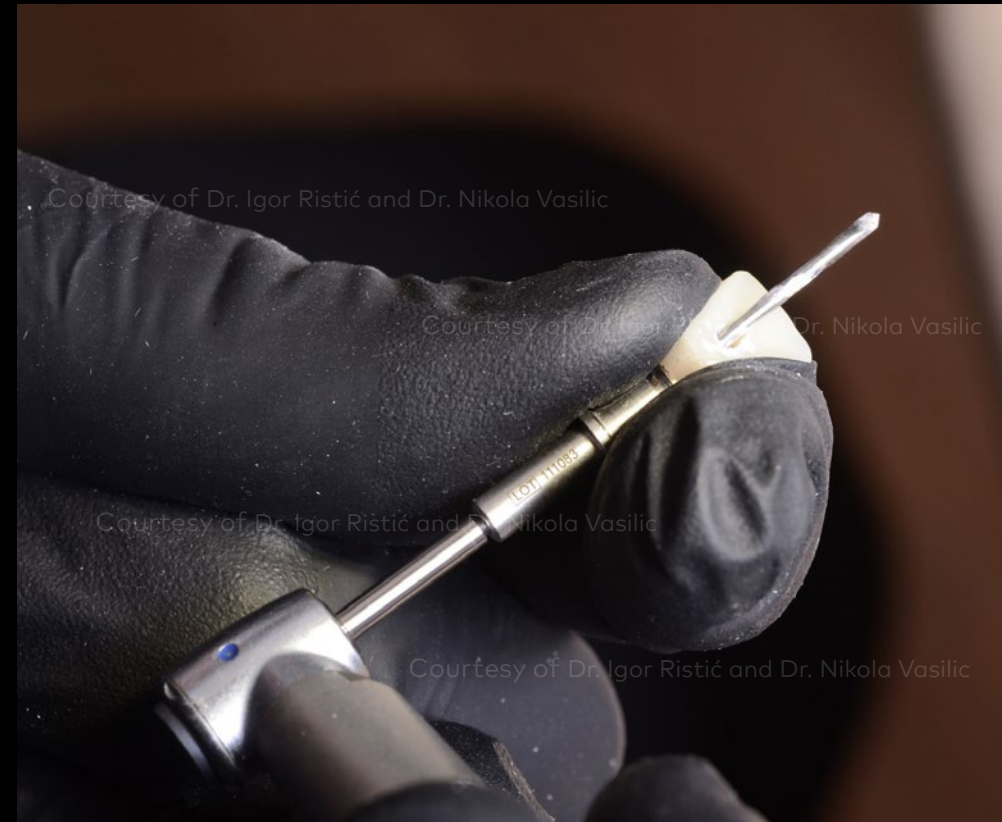## Surgical procedure

## Restorative procedure

## Outcome



Finalizing Temporary Snap Abutment for fixation



Drilling the screw access hole with Apical Drill

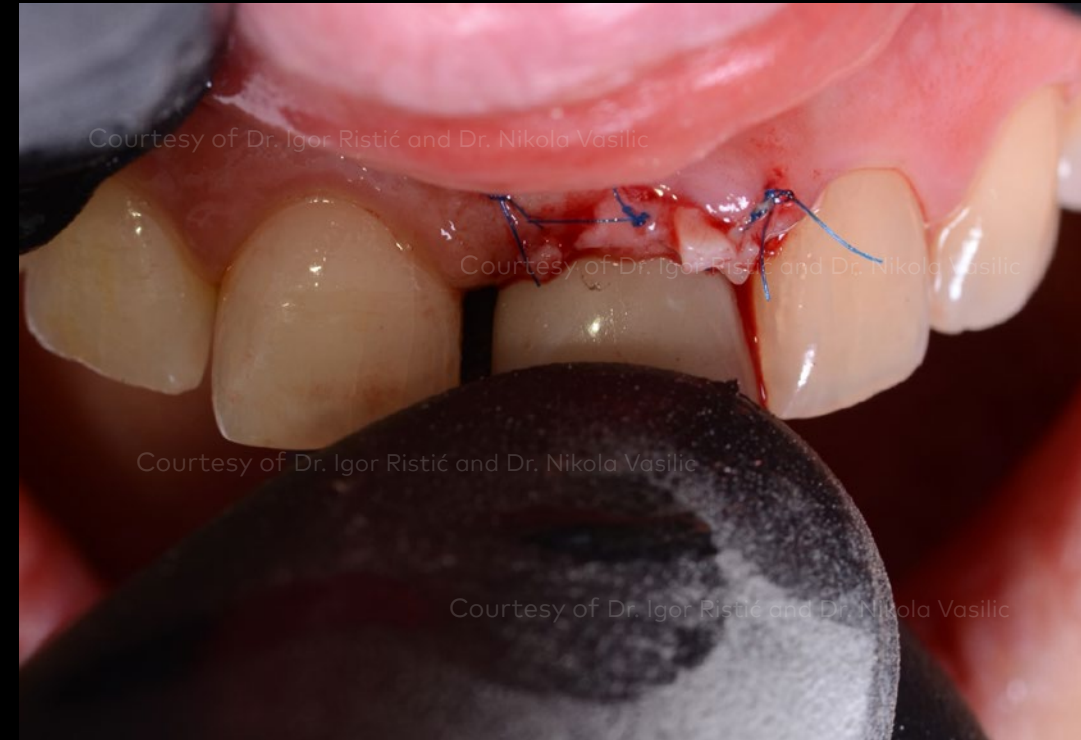## Initial clinical situation

## Treatment planning

## Surgical procedure

## Restorative procedure

## Outcome



Widening the screw access hole with a diamond burr

Placing of temporary crown

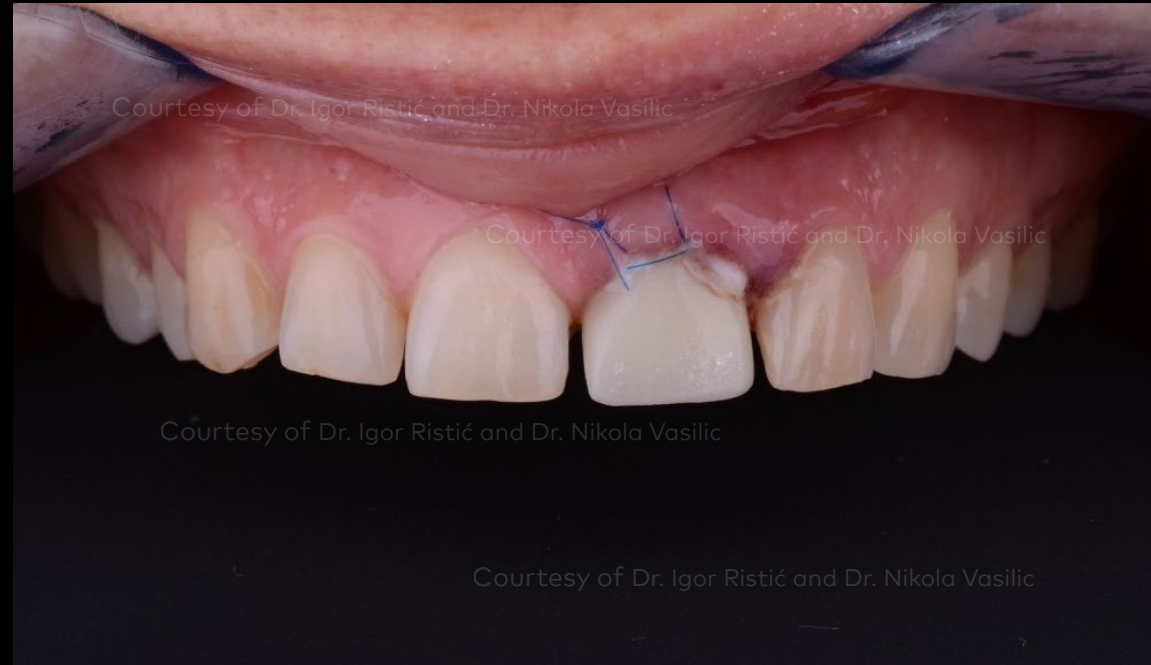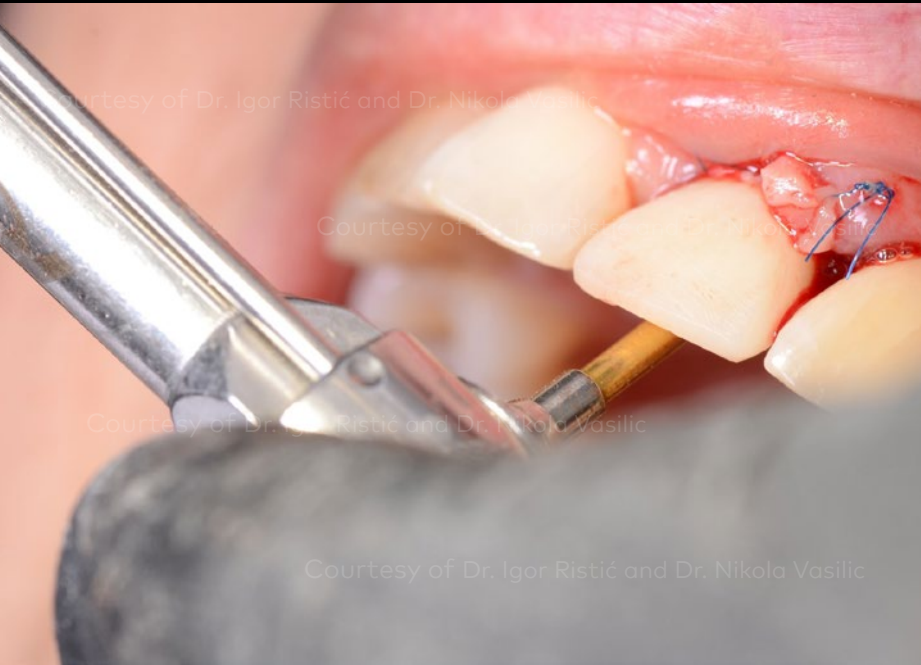## Initial clinical situation

## Treatment planning

## Surgical procedure

## Restorative procedure

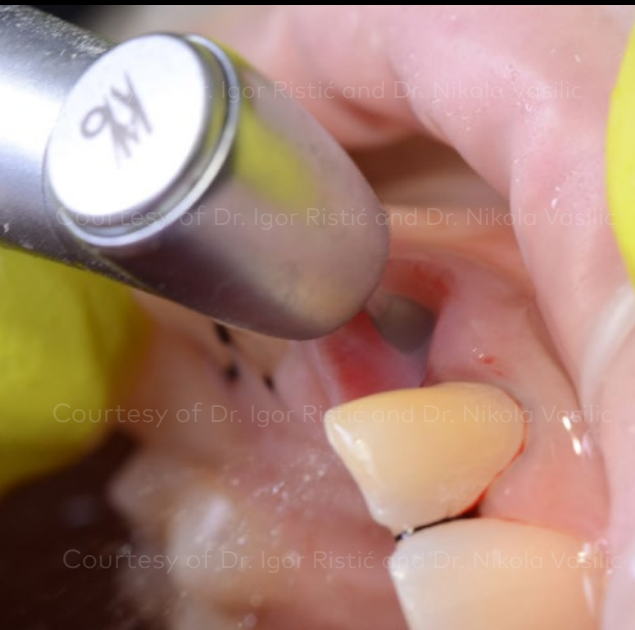## Outcome



Torque value is 15 Ncm for Temporary Snap Abutment

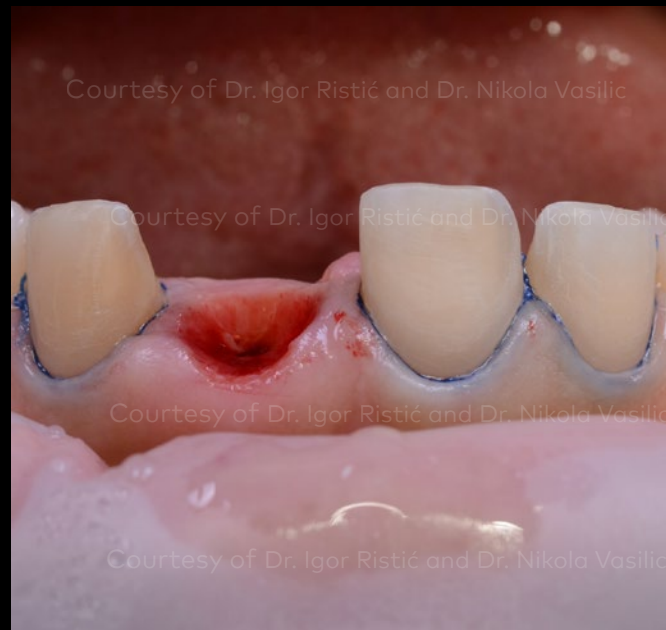Immediate postoperative situation with temporary crown

## Initial clinical situation



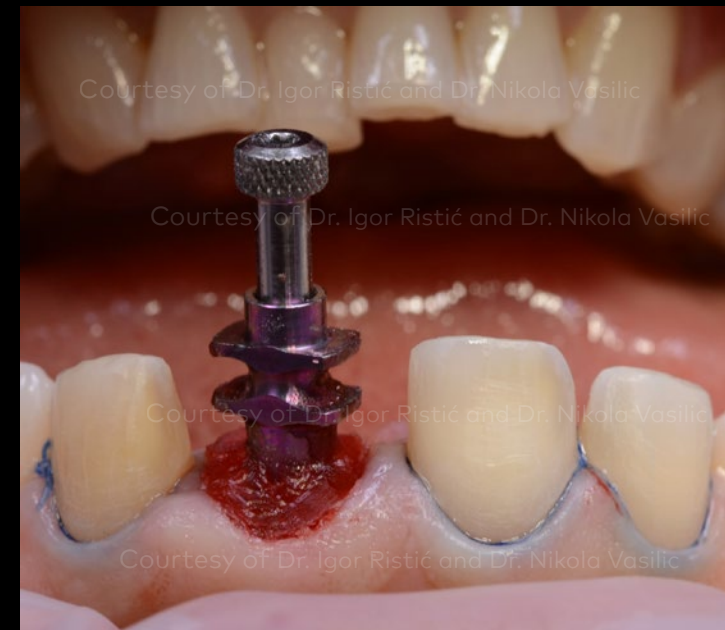Soft tissue final re-shaping prior to impression procedure

## Treatment planning



Minimal preparation of surrounding teeth

## Surgical procedure



Individualized impression coping prior to impression procedure

## Restorative procedure

## Outcome

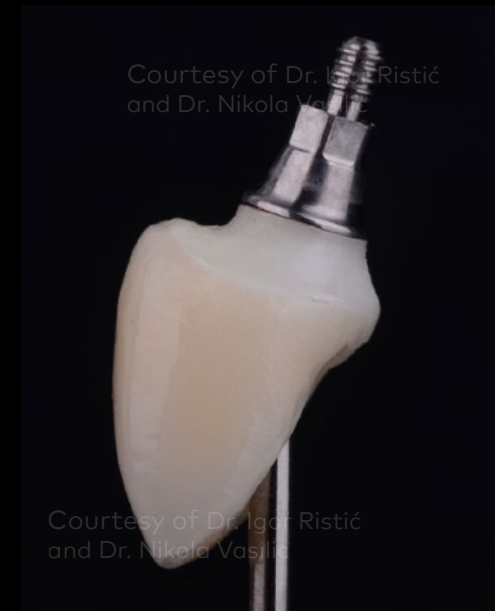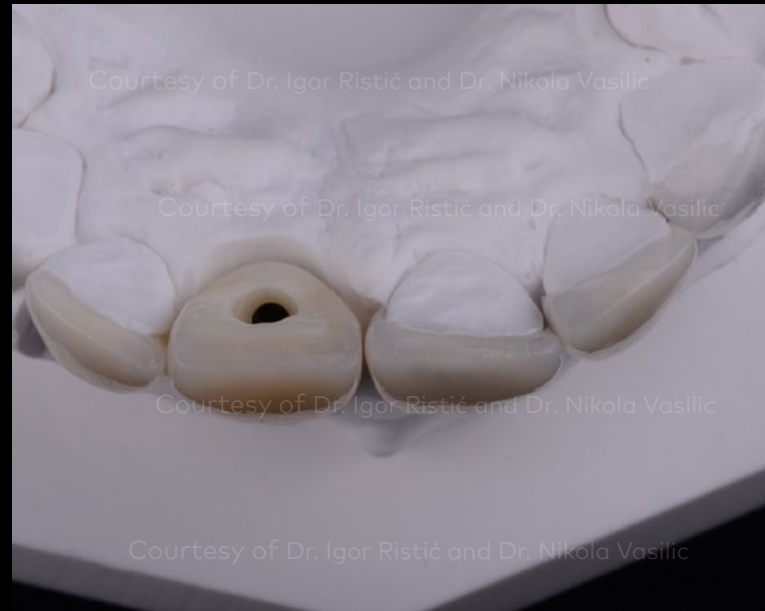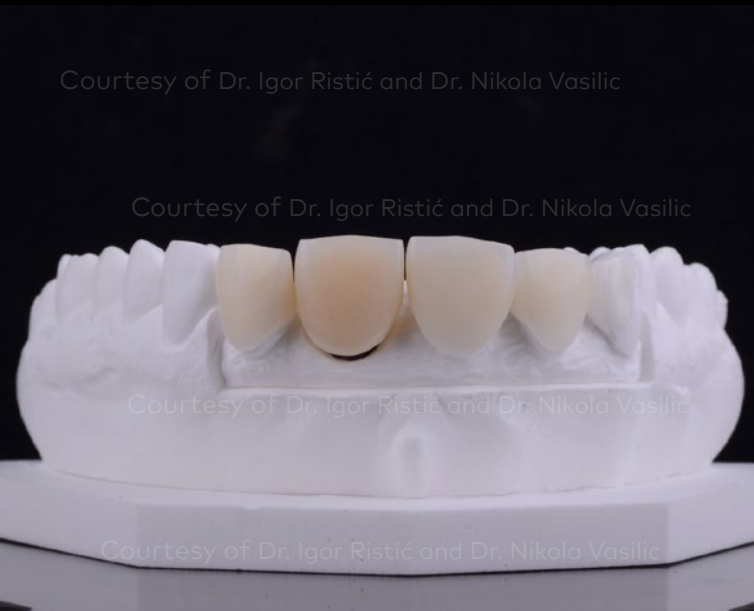## Initial clinical situation

## Treatment planning

## Surgical procedure

## Restorative procedure

## Outcome



NobelProcera® ASC Abutment and veneers on model

Restorations on model, palatal view

Individualized NobelProcera® ASC Abutment in zirconia veneered with e.max Ceram

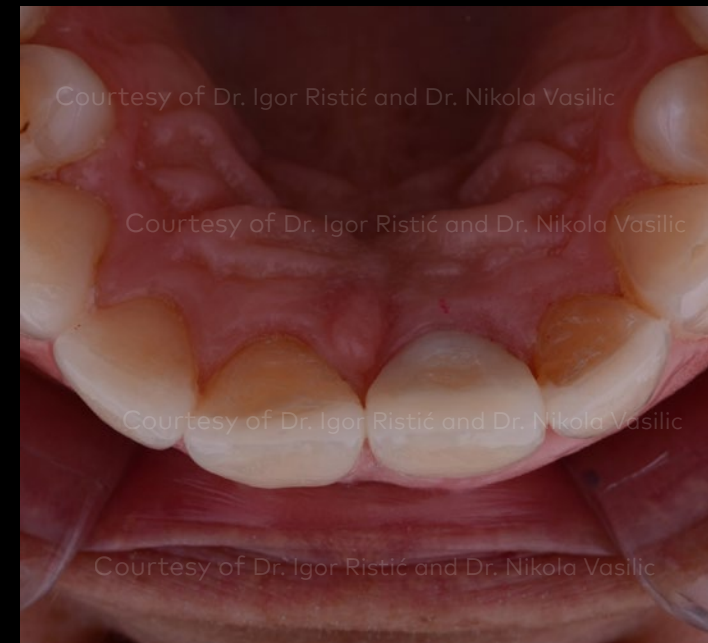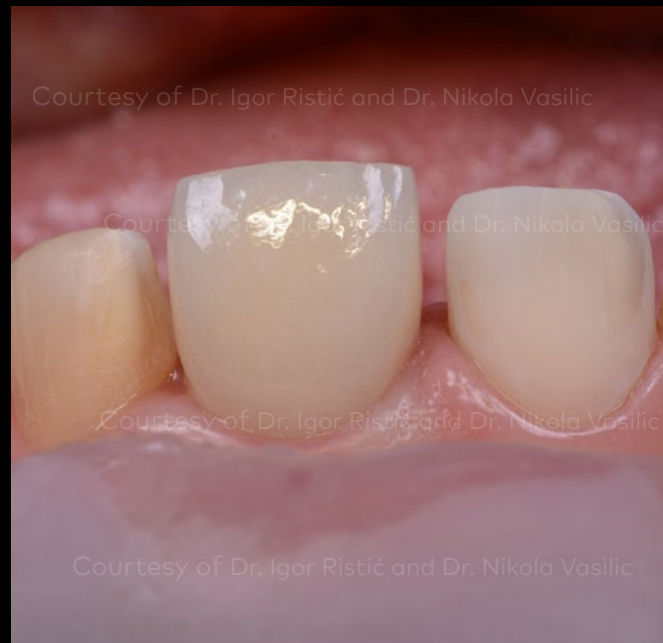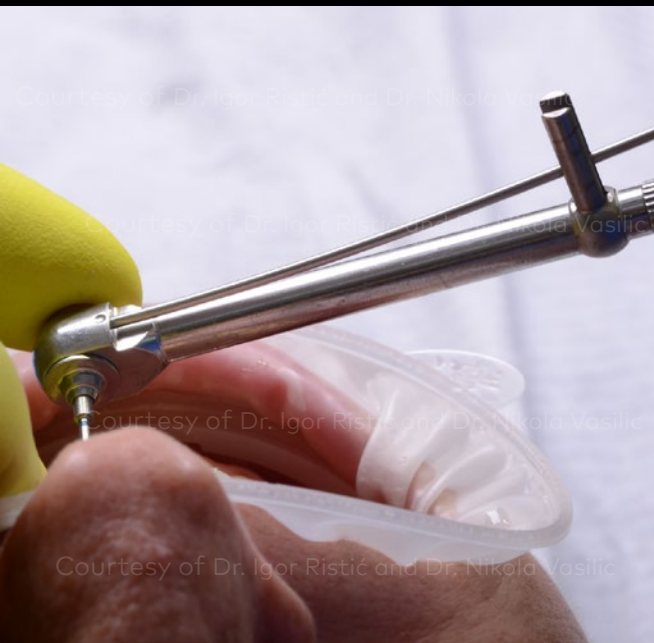## Initial clinical situation

## Treatment planning

## Surgical procedure

## Restorative procedure

## Outcome



Final torque of Individualized NobelProcera® ASC Abutment is 35 Ncm

Implant restoration immediately after tightening

Rest of the restorations bonded on teeth. Screw access hole filled with Teflon™ and light cured composite



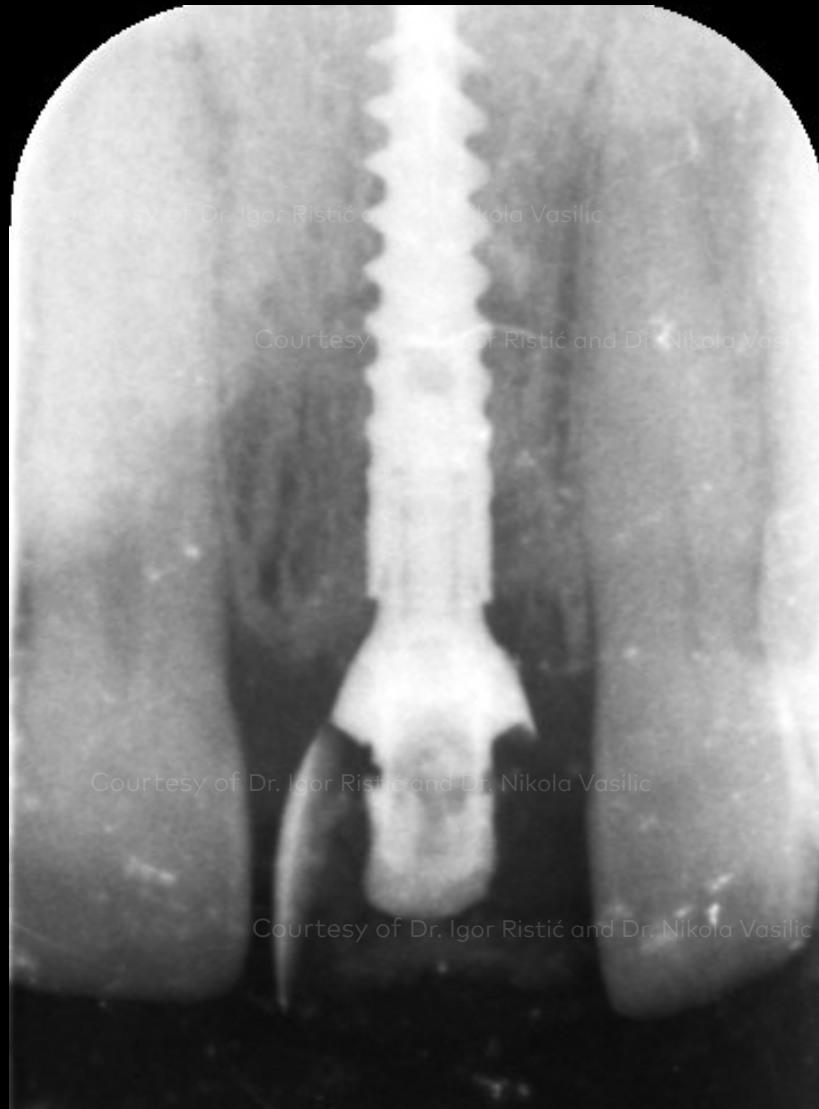## Initial clinical situation

## Treatment planning

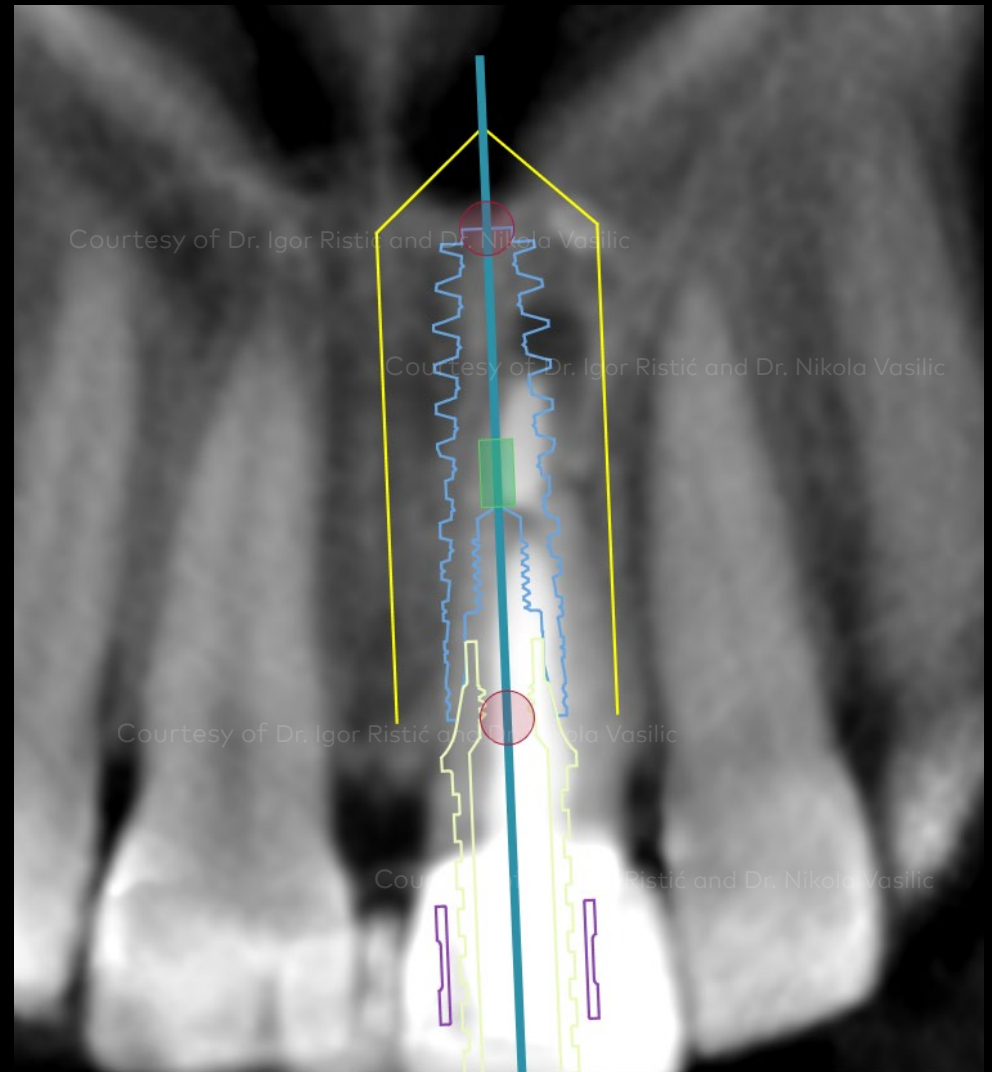
## Surgical procedure

## Restorative procedure

## Outcome



Postoperative intraoral X-ray



Superimposition of the digital planning as previously done in NobelClinician® software

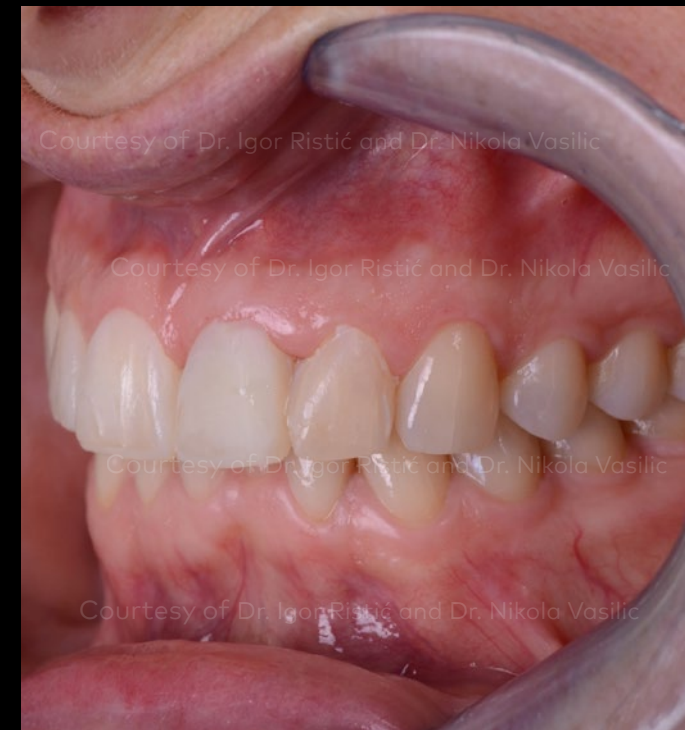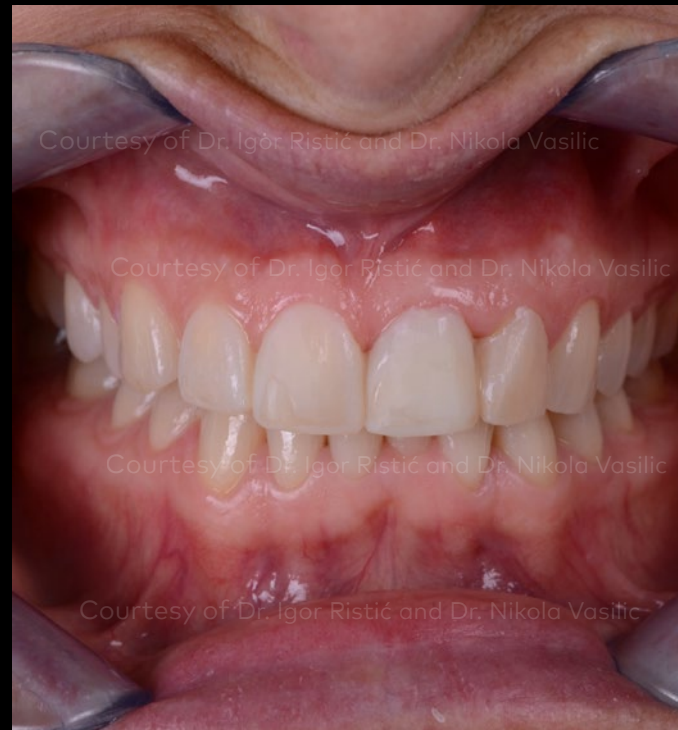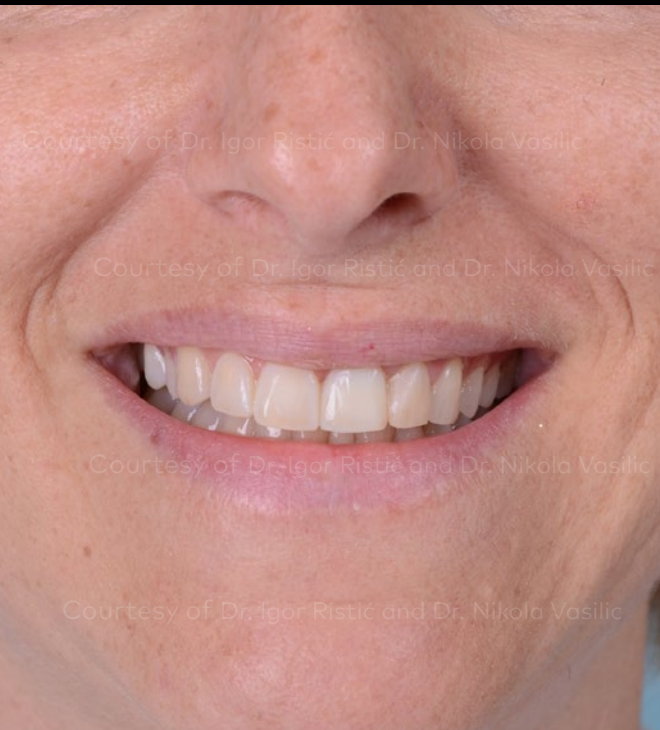## Initial clinical situation

## Treatment planning

## Surgical procedure

## Restorative procedure

## Outcome



Mock-up for finalization of the treatment. Veneers on upper central right and lateral incisors and upper left lateral incisor and canine are planned

Intraoral view of the mock-up

Lateral mock-up view

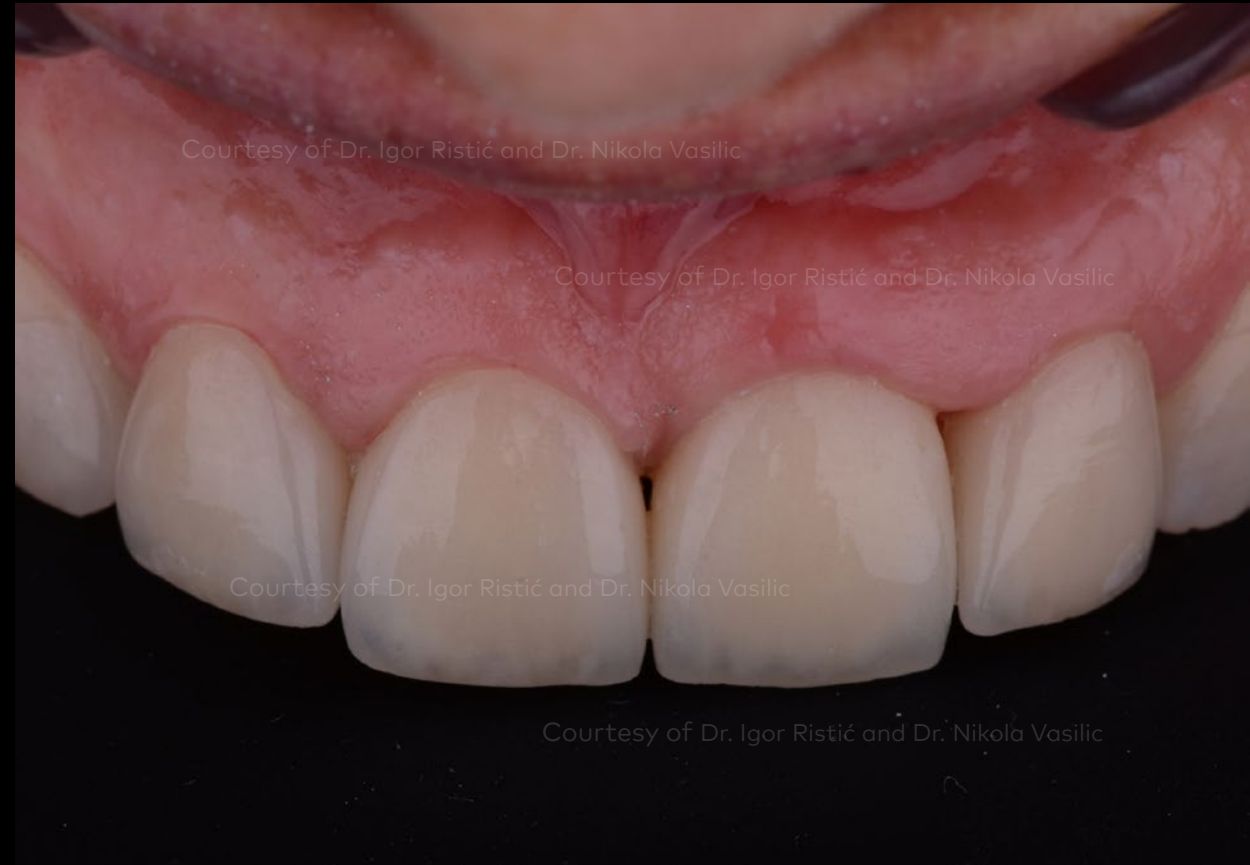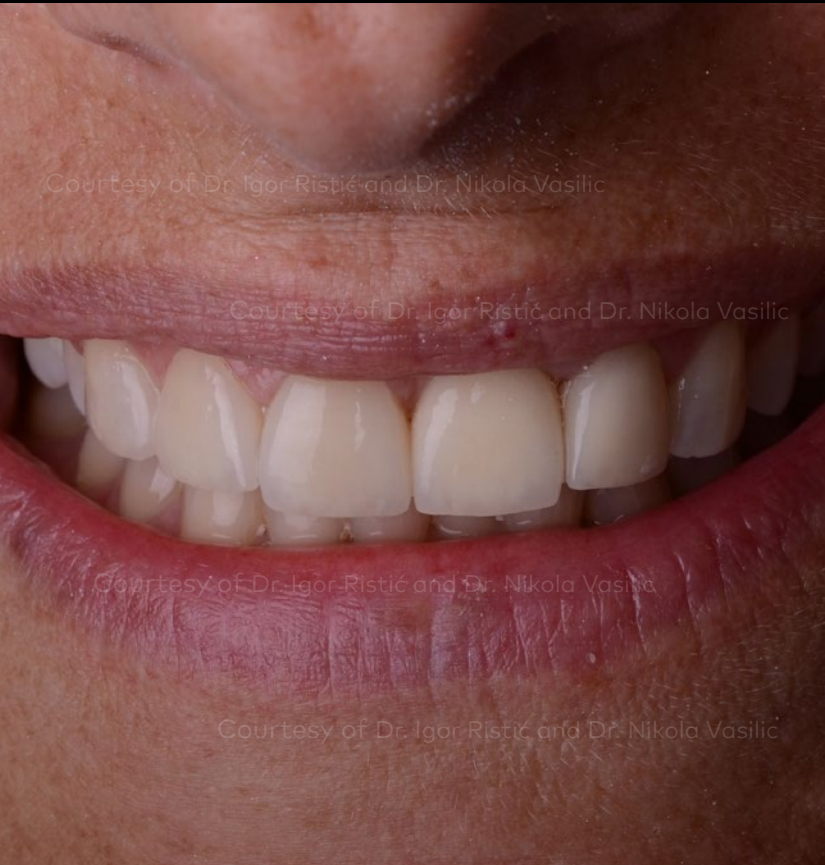**Initial clinical situation**

**Treatment planning**

**Surgical procedure**

**Restorative procedure**

**Outcome**



Intraoral view of finished NobelProcera® ASC Abutment

Perfect blend of restorative materials with natural tissues, immediate postoperative photo

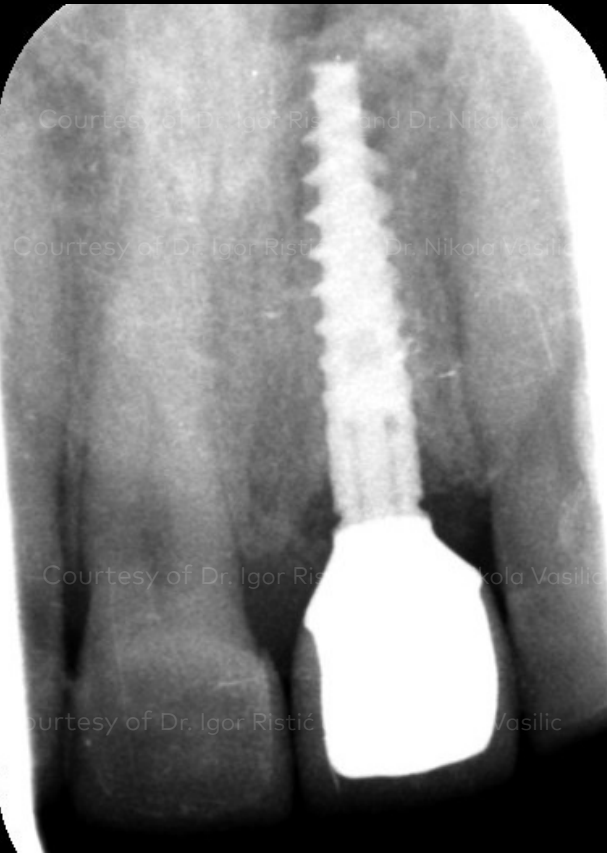## Initial clinical situation

## Treatment planning

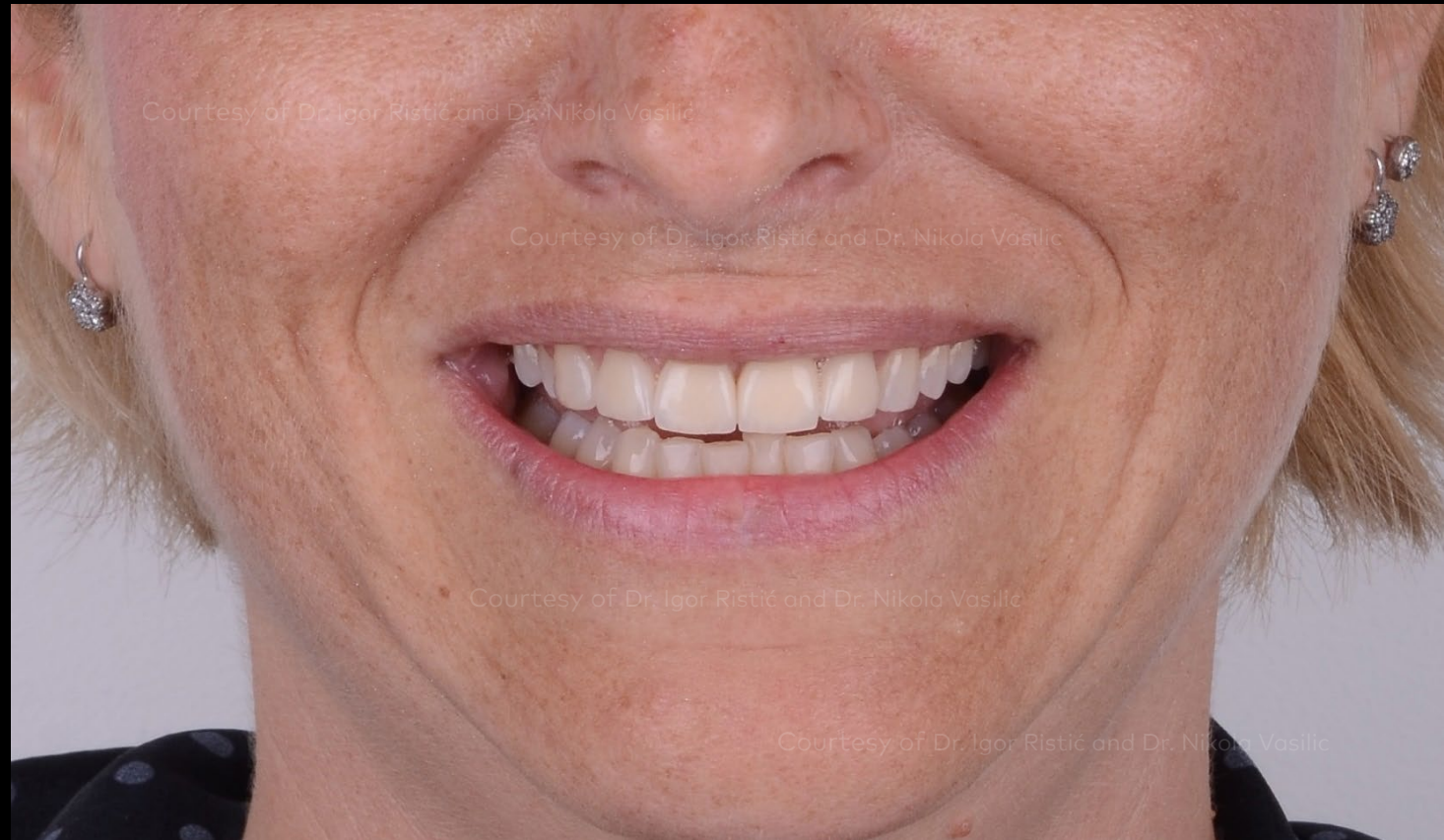## Surgical procedure

## Restorative procedure

## Outcome



X-ray with implant and restoration after final prosthetic delivery



Final smile of the satisfied patient

## Case courtesy of Igor Ristić and Nikola Vasilic



GMT 63173 GB 1906 © Nobel Biocare Services AG, 2019. All rights reserved. creos xenogain is distributed by: Nobel Biocare. Legal manufacturer: Nibec Co., Ltd. Iwol electricity-electronic Agro-industrial Complex, 116 Bamdi-gil, Iwol-myeon, Jincheon-gun, Chungcheongbuk-do, 27816 Korea. KaVo is either registered trademark or trademark of Kaltenbach & Voigt GmbH. DTX Studio, Nobel Biocare, the Nobel Biocare logotype and all other trademarks are, if nothing else is stated or is evident from the context in a certain case, trademarks of Nobel Biocare. Please refer to [nobelbiocare.com/trademarks](https://nobelbiocare.com/trademarks) for more information. Other trademarks are either registered trademarks or trademarks of their respective owners. Product images are not necessarily to scale. Disclaimer: Some products may not be regulatory cleared/released for sale in all markets. Please contact the local Nobel Biocare sales office for current product assortment and availability. For prescription use only. Caution: Federal (United States) law restricts this device to sale by or on the order of a licensed clinician, medical professional or physician. See Instructions For Use for full prescribing information, including indications, contraindications, warnings and precautions. Nobel Biocare does not take any liability for any injury or damage to any person or property arising from the use of this clinical case. This clinical case is not intended to recommend any measures, techniques, procedures or products, or give advice, and is not a substitute for medical training or your own clinical judgement as a healthcare professional. Viewers should never disregard professional medical advice or delay seeking medical treatment because of something they have seen in this clinical case. Full procedure is not shown. Certain sequences have been cut. Not all medical devices used during surgery are Nobel Biocare devices. Nobel Biocare recommends that manufacturer's IFUs are followed. Please refer to applicable IFUs for full instructions.