

CLINICAL CASE



Navigated surgery with fully digital workflow

Armando Lopes
Portugal





Armando Lopes

Patient

Healthy, female, 44

Clinical situation

Patient missing mandibular premolar and molar teeth for several years

Surgical solution

Flapless and open-flap surgery with NobelParallel™ Conical Connection NP implants, inserted using X-Guide™

Restorative solution

Multi-unit Abutment Plus and TempShell

Surgery date

October 2018

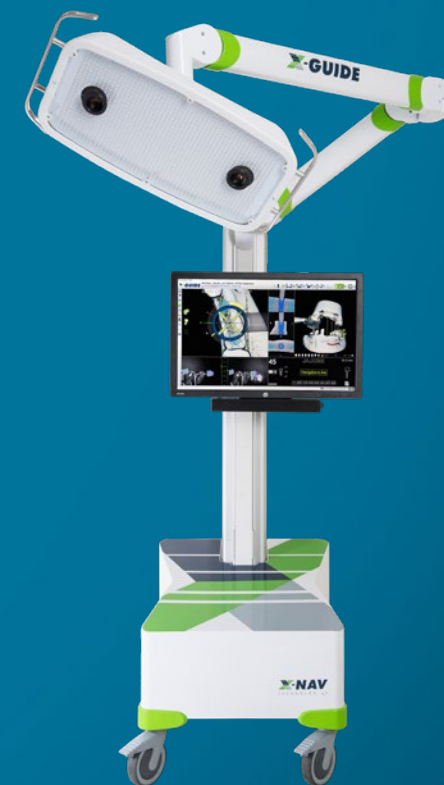Total treatment time

Same-day planning, surgery and provisionalization

Tooth positions

35 and 37

"In this clinical case, I followed a fully digital workflow during both the surgical stage (with DTX Studio™ Implant and X-Guide™) and the prosthetic stage (with DTX Studio Lab). This high-precision and straightforward approach helped me to treat my patient efficiently."

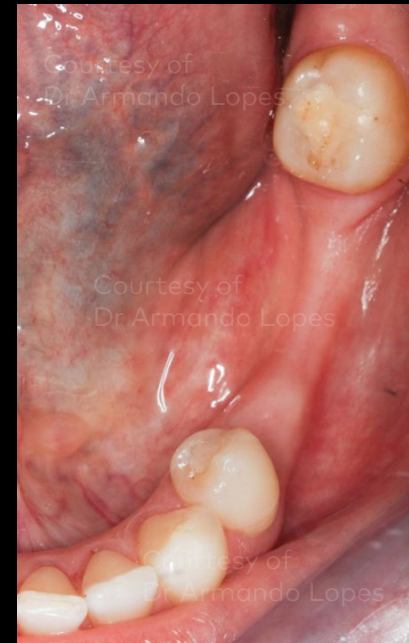
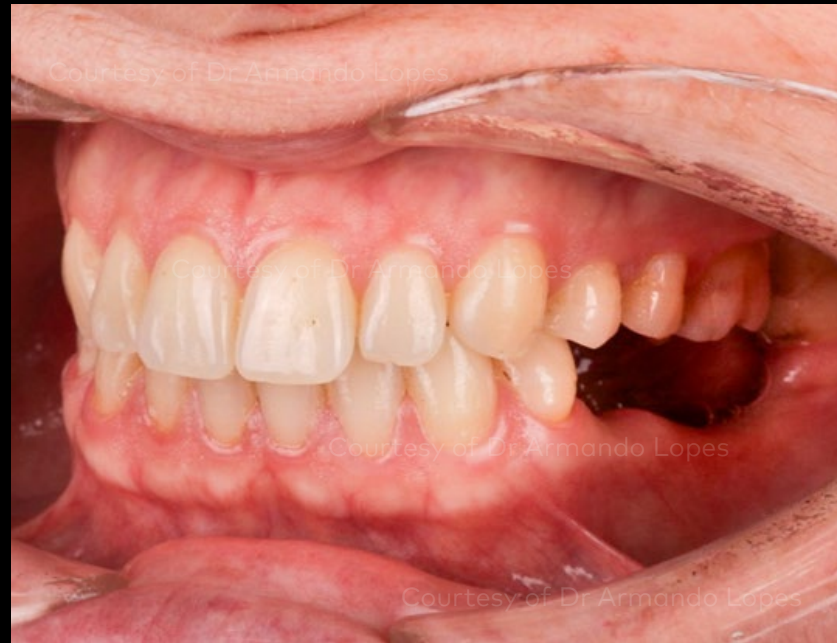
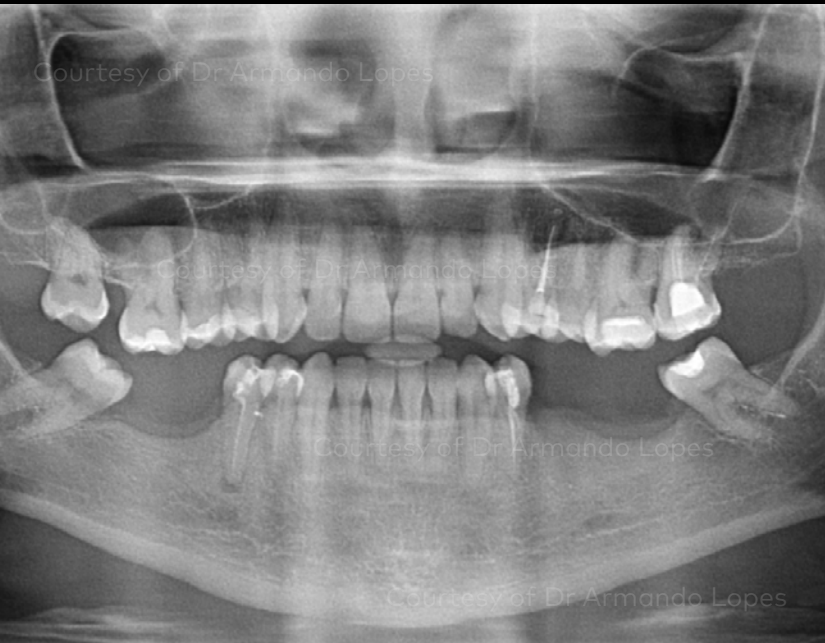Initial clinical situation

Treatment planning

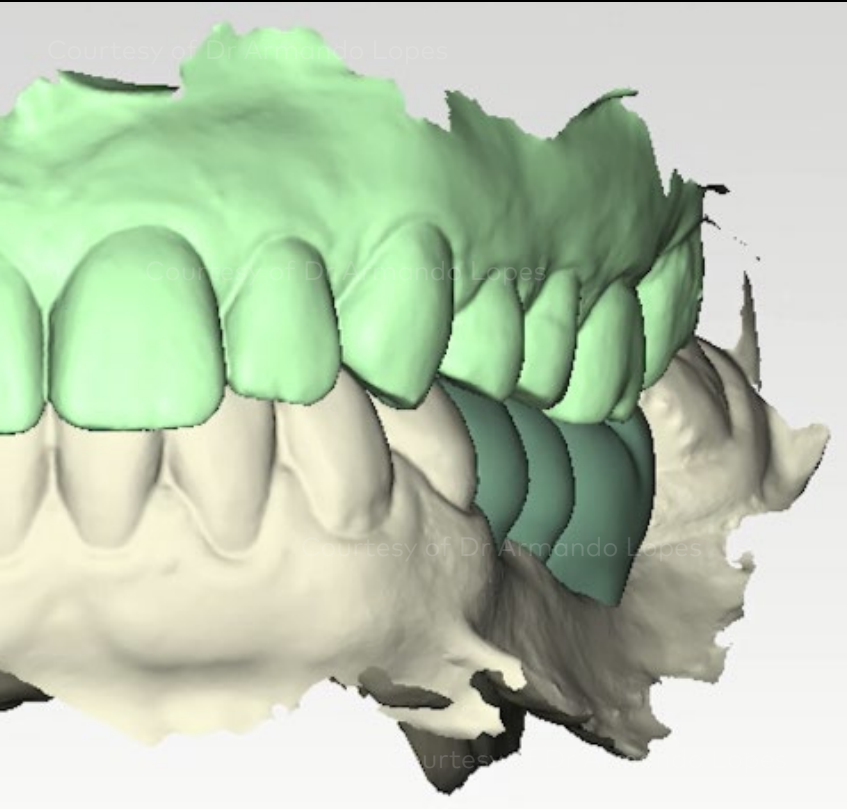Surgical procedure

Outcome

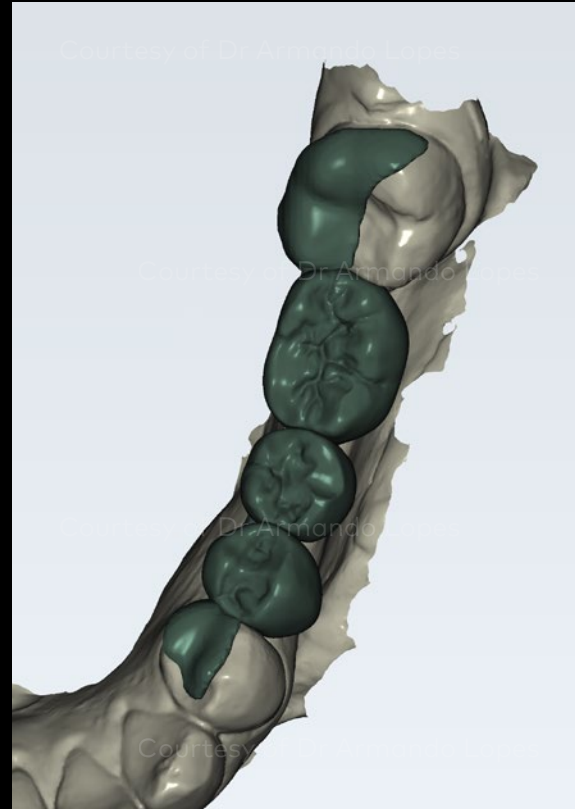

Radiographic and clinical images at presentation showing defects in both mandibular quadrants, where the patient has been missing premolar and molar teeth for several years. This clinical case will focus only on restoration of the narrow ridge between tooth positions 35-37, where free-hand, open flap surgery could be challenging.

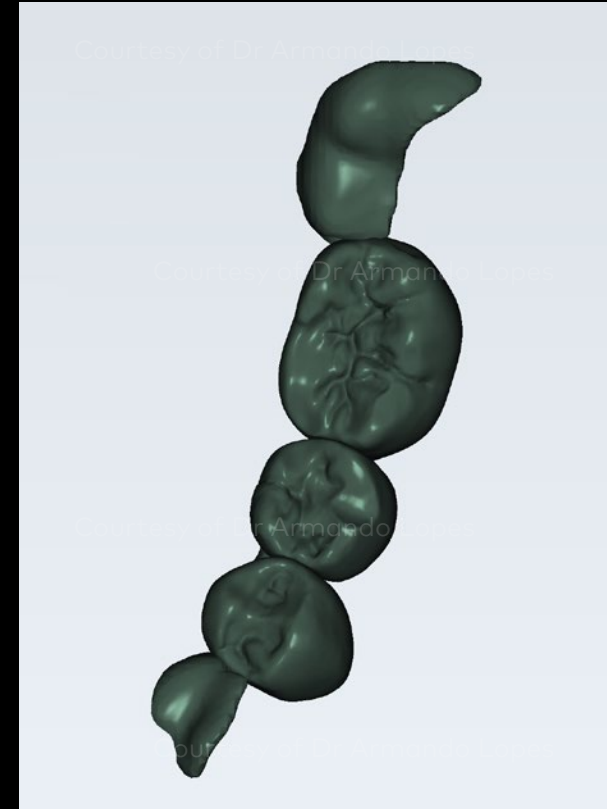Initial clinical situation



Treatment planning



Surgical procedure



Outcome

Buccal view from DTX Studio Lab showing prosthetic design based on implant location, in reference to hard and soft tissues, and planned with the opposing teeth in occlusion.

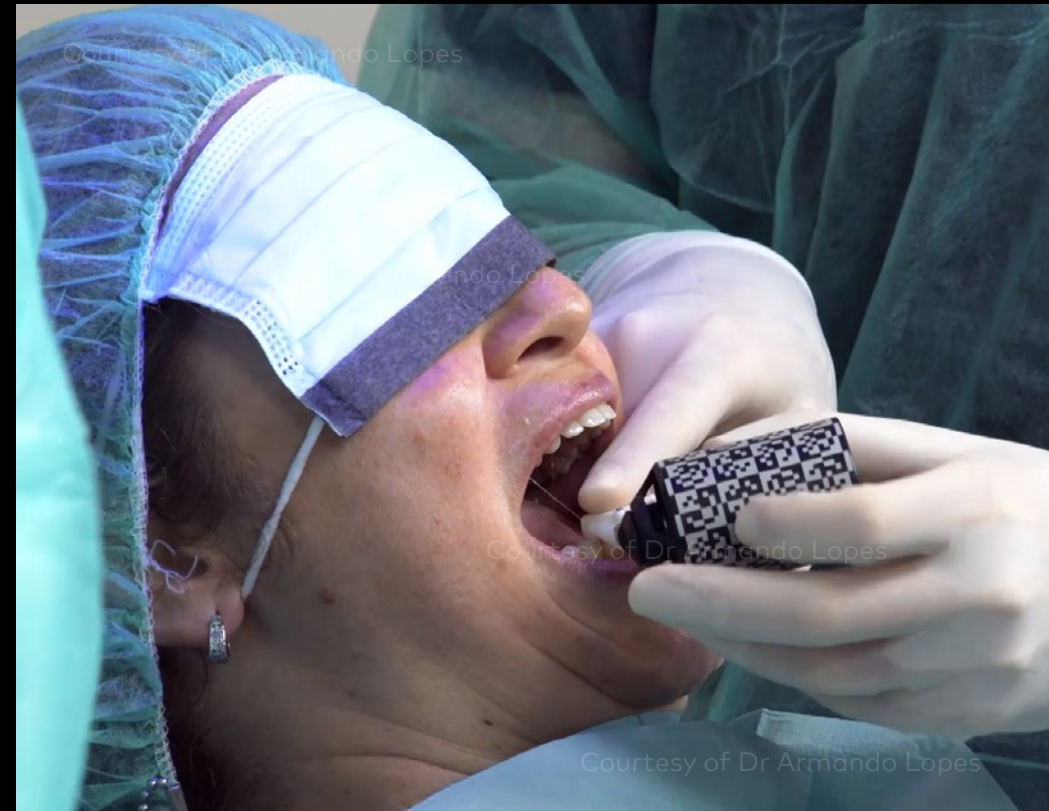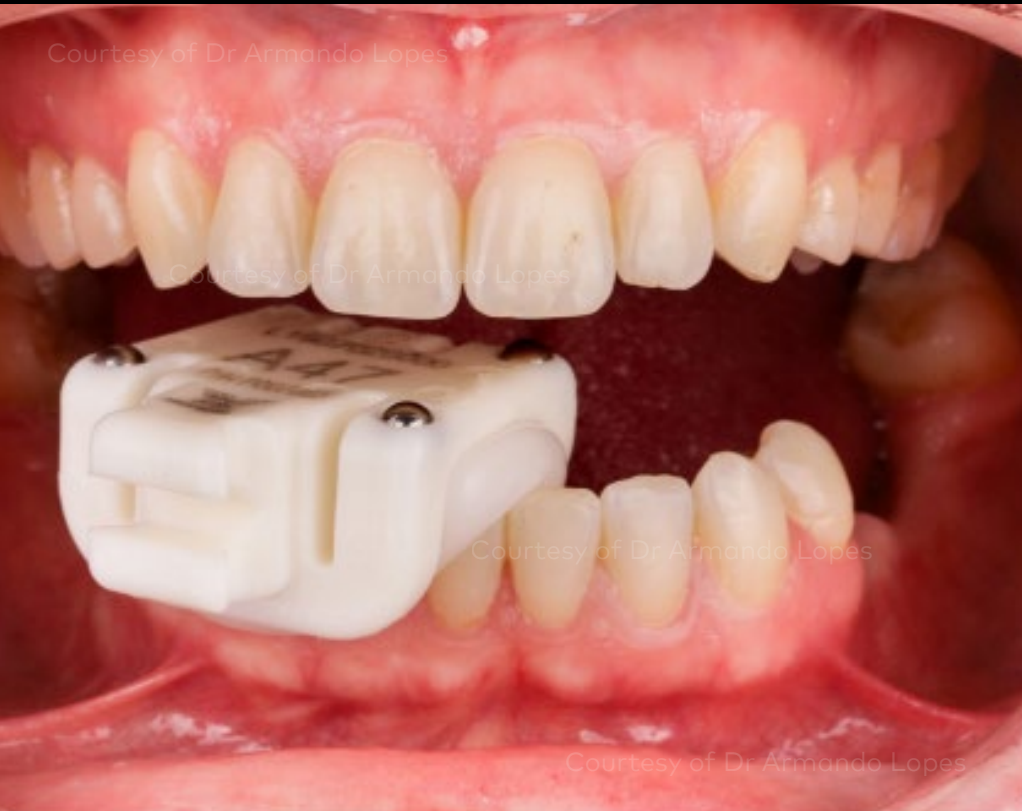The digital treatment plan in DTX Studio Lab was used to design individualized provisional TempShell restorations, shown here on the dental scan. The files encoding the TempShell provisional restorations were exported from DTX Studio Lab for in-lab production.

Initial clinical situation

Treatment planning

Surgical procedure

Outcome



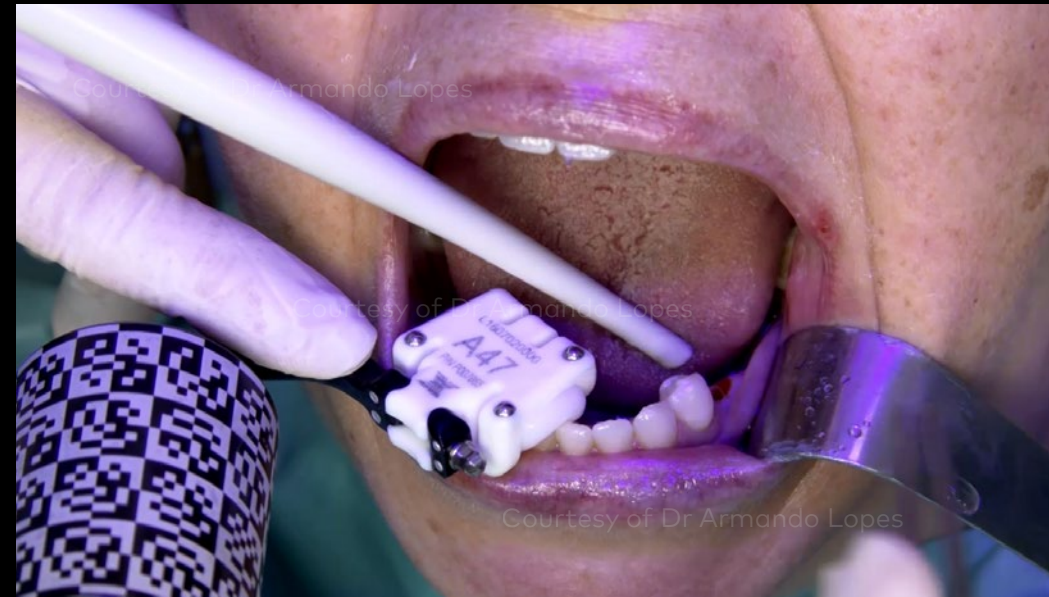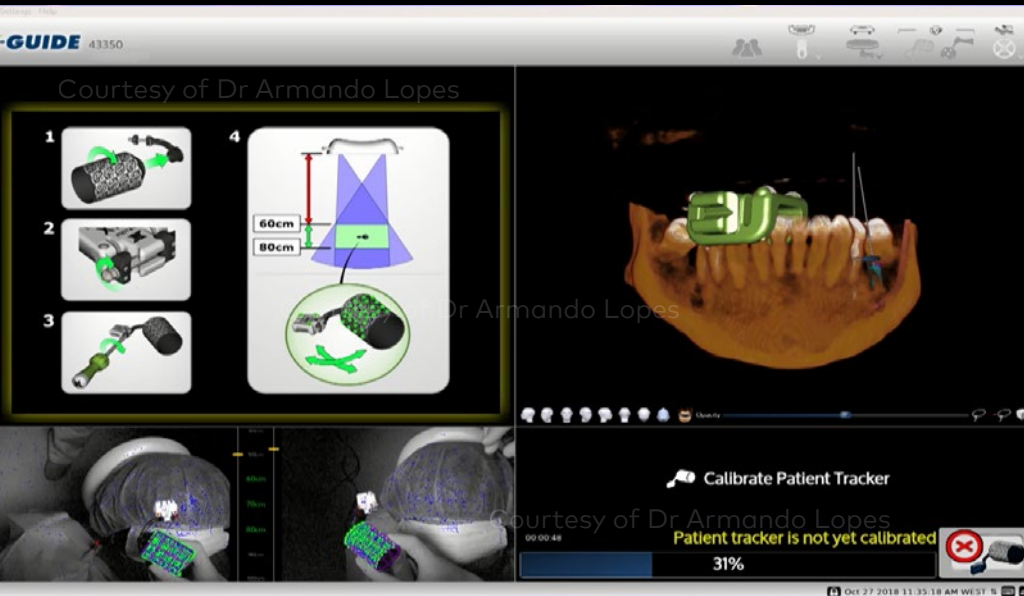A lightweight X-Clip is placed into the patient's mouth and remains throughout the surgical procedure. With the X-Clip in the patient's mouth, a further CBCT is taken in the usual way. The X-Clip is connected to a Tracker Arm to ensure proper registration between the patient, the CBCT and the surgical plan.

Initial clinical situation

Treatment planning

Surgical procedure

Outcome



The X-Guide undergoes a 3-step calibration to prepare it to guide drills and position implants in real-time with dynamic 3D navigation.

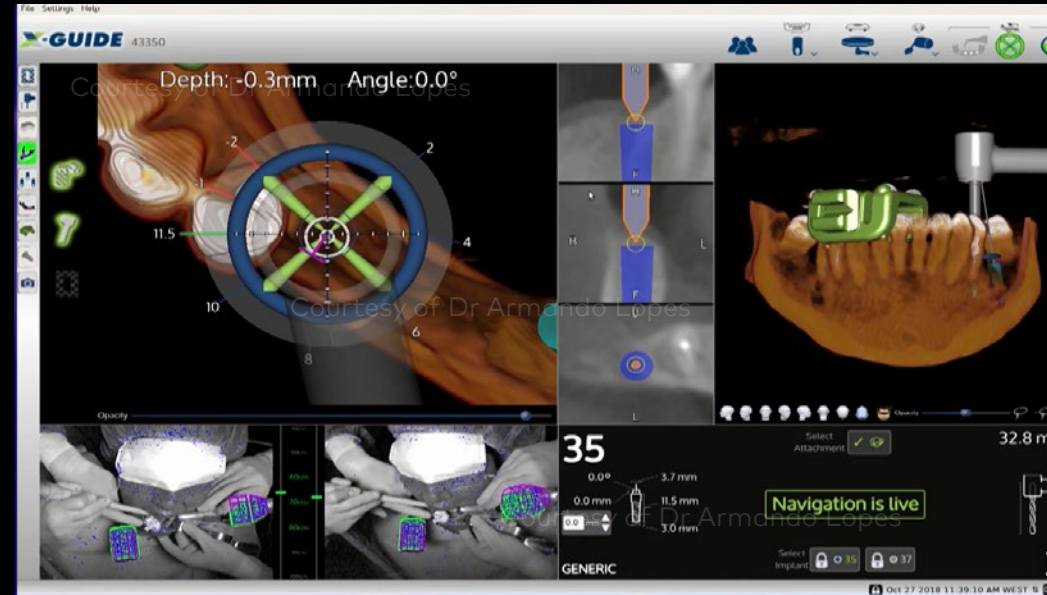At implant position 35, due to there being >5 mm of keratinized gingiva (buccolingually), a Tissue Punch was used to access the underlying bone.

Initial clinical situation

Treatment planning

Surgical procedure

Outcome



The Precision Drill tip is touched against the sterile Go-Plate, which informs the X-Guide of the exact drill length.

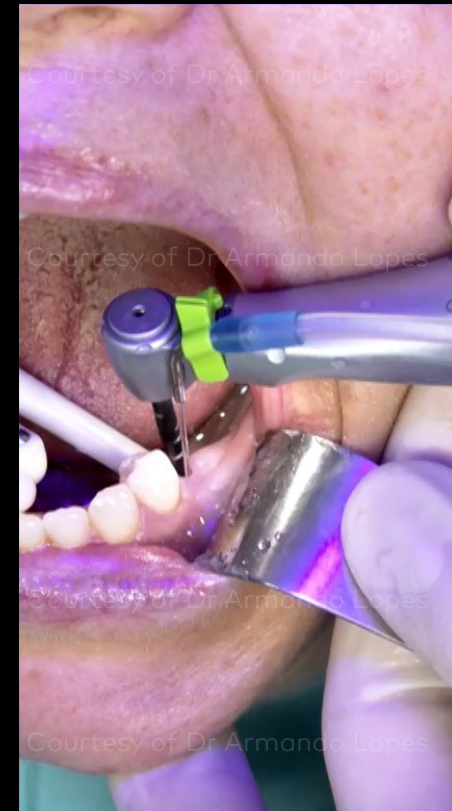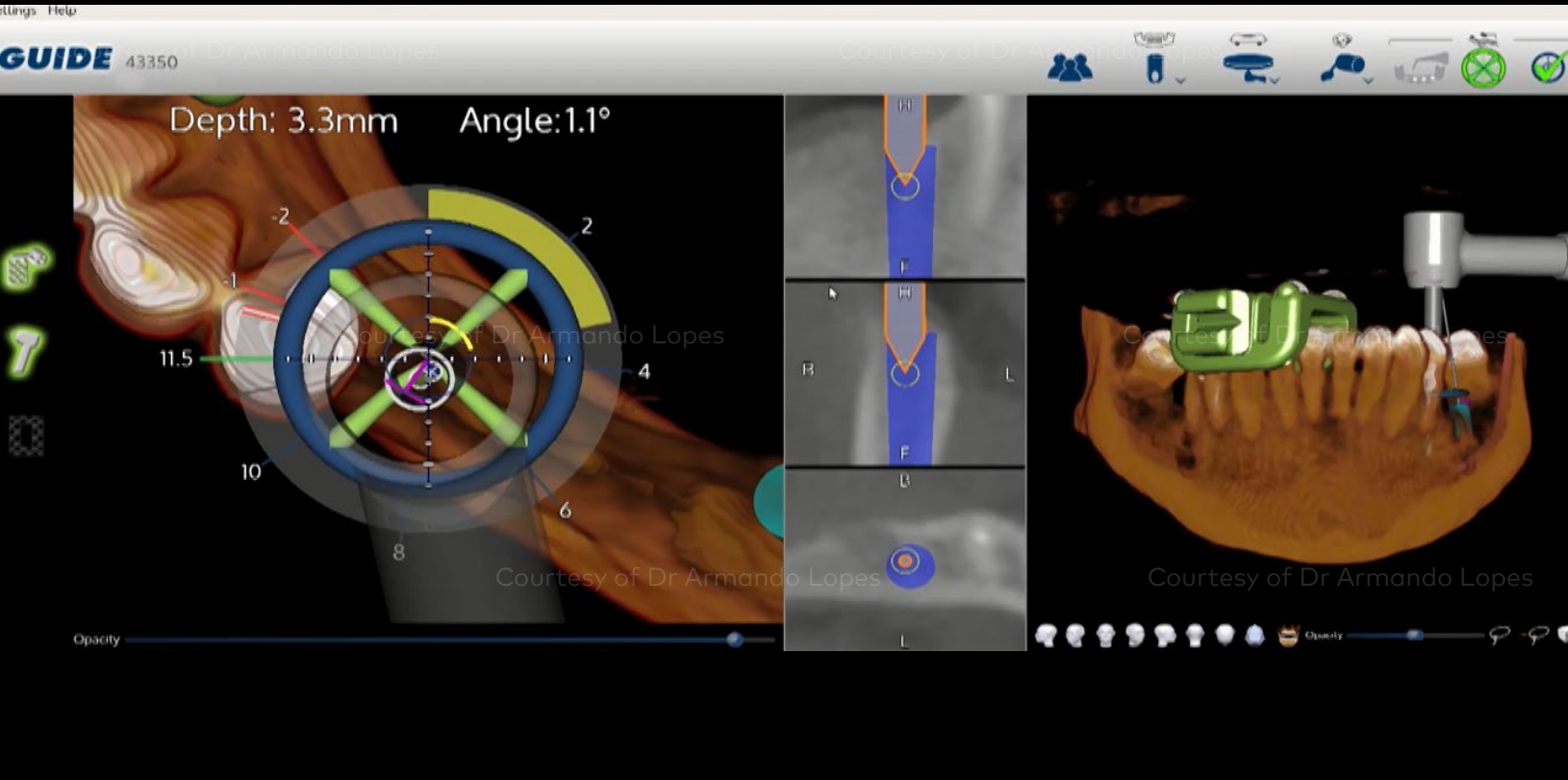
Precision Drill osteotomy preparation under real-time 3D guidance at implant position 35.

Initial clinical situation

Treatment planning

Surgical procedure

Outcome



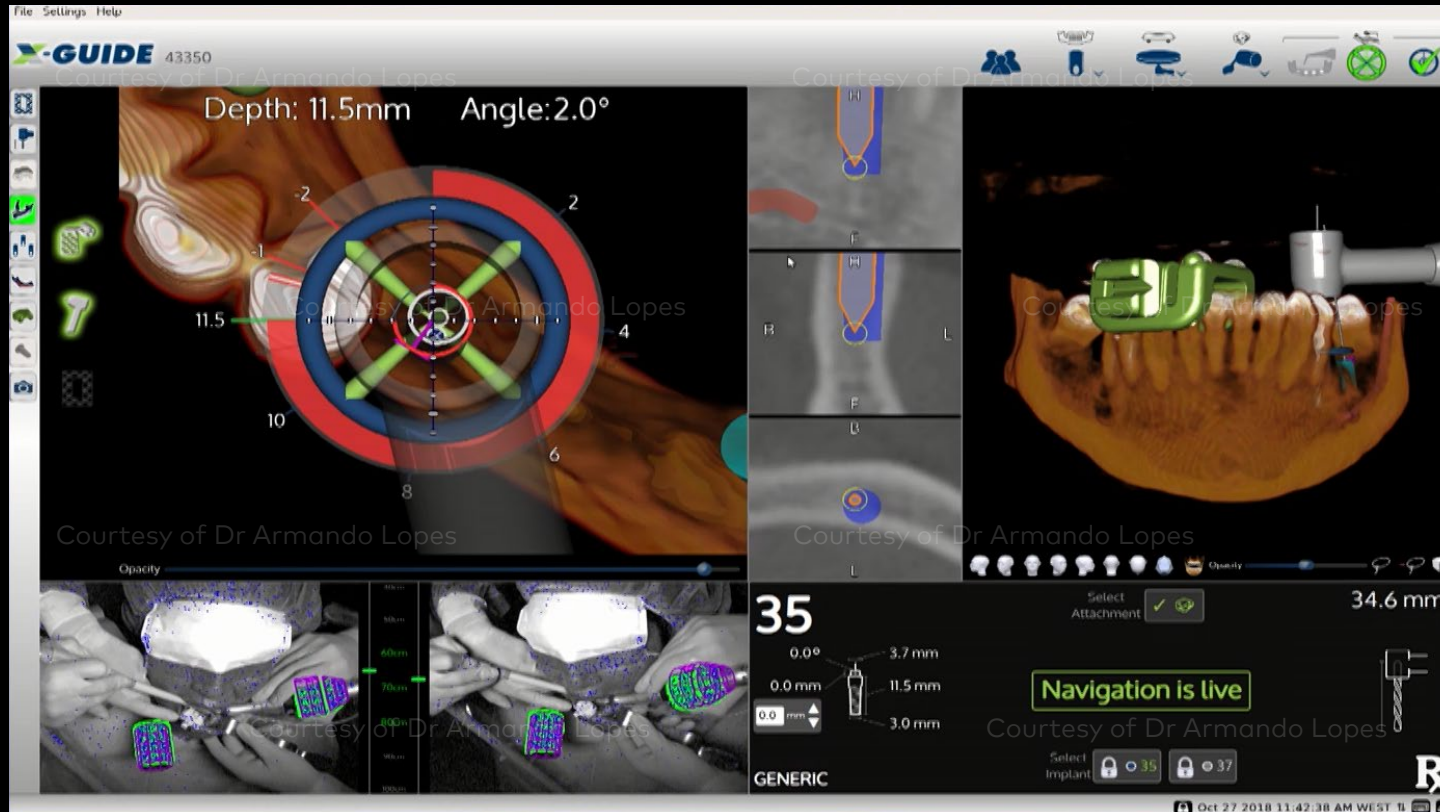3.3 mm depth into the osteotomy preparation at implant position 35. Increasing depth is indicated by the yellow depth indicator bar on the target view and by the drill position on the cross-sectional view.

Initial clinical situation

Treatment planning

Surgical procedure

Outcome



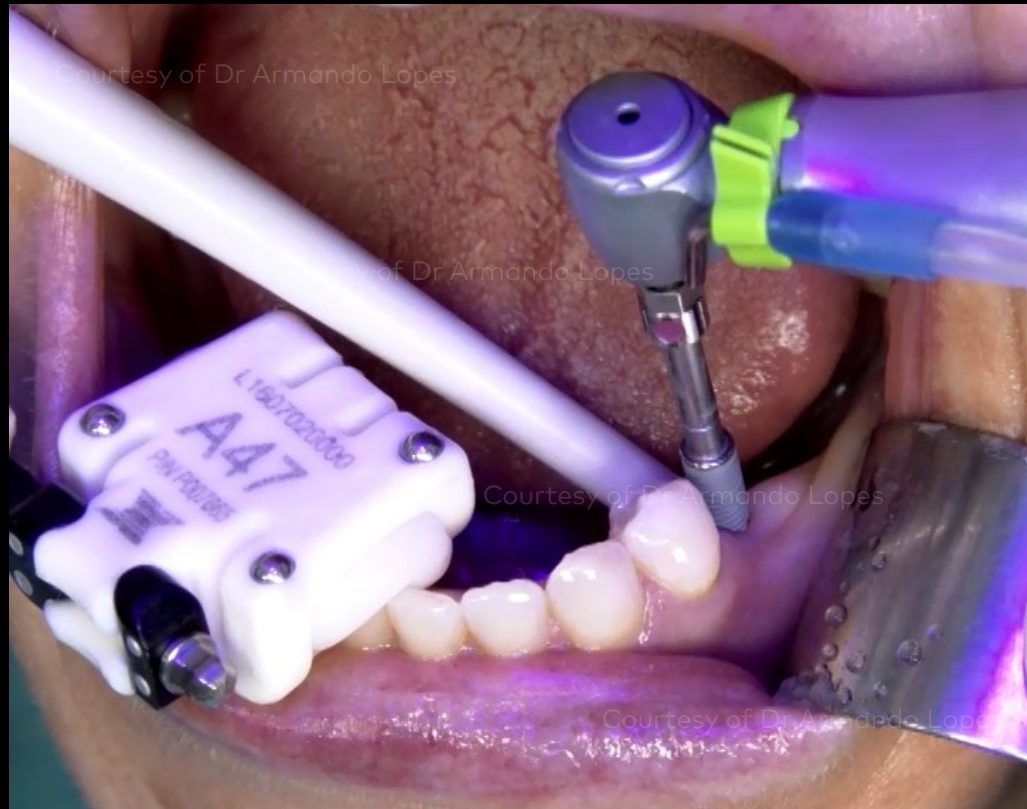The depth indicator bar turns red when the planned implant position of 11.5 mm depth is reached. Camera views, 3D view and the implant information panel are shown in parallel.

Initial clinical situation

Treatment planning

Surgical procedure

Outcome



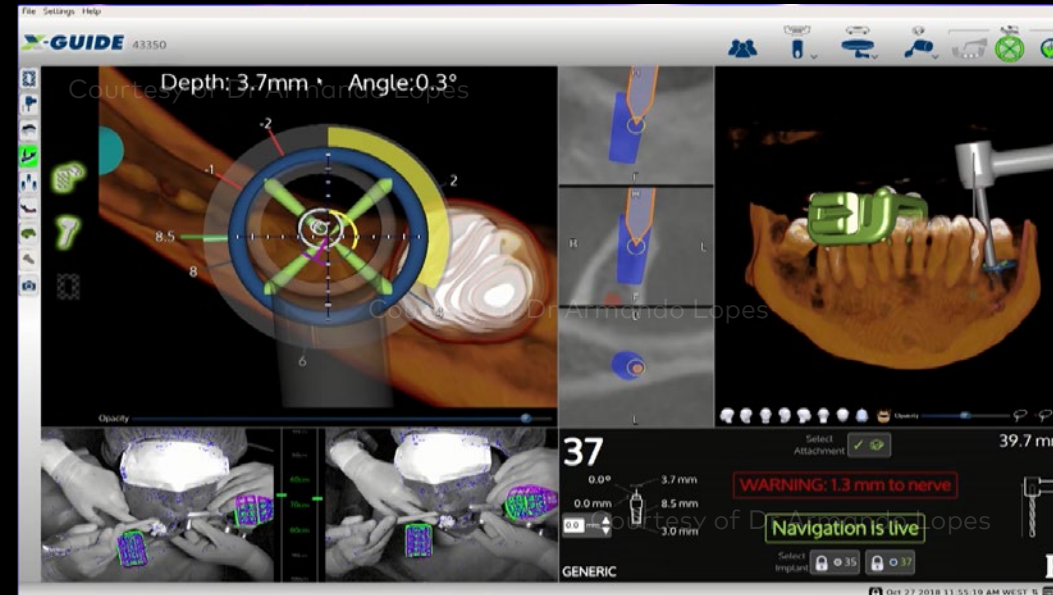
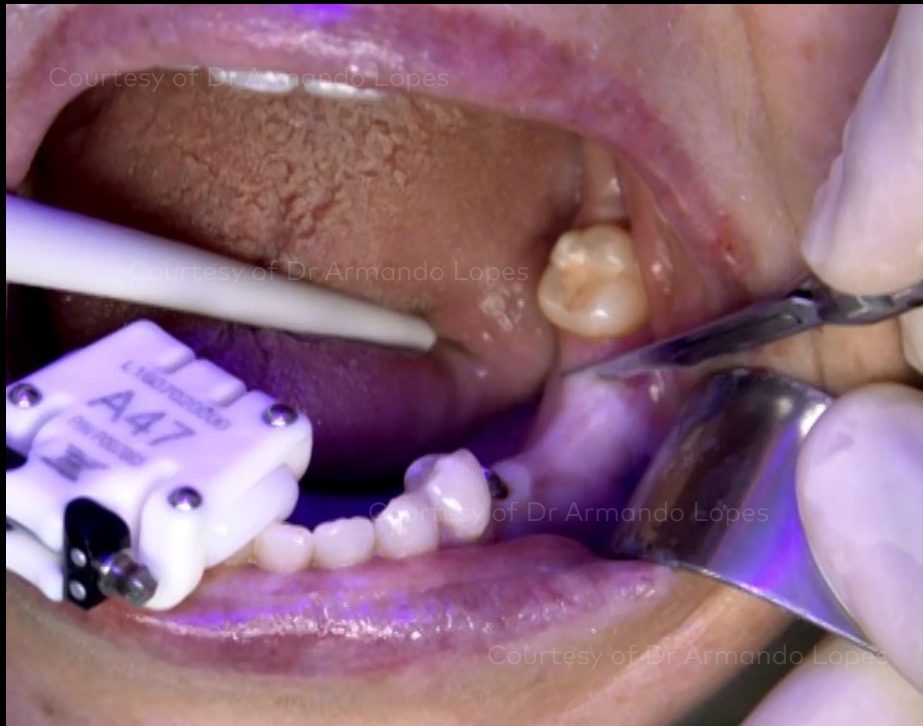Insertion of the NobelParallel™ Conical Connection NP 3.75 × 11.5 mm implant at position 35.

Initial clinical situation

Treatment planning

Surgical procedure

Outcome



At implant position 37, there was <5 mm of keratinized gingiva (buccolingually), so a flap was raised to access the bone and maximize soft tissue preservation.

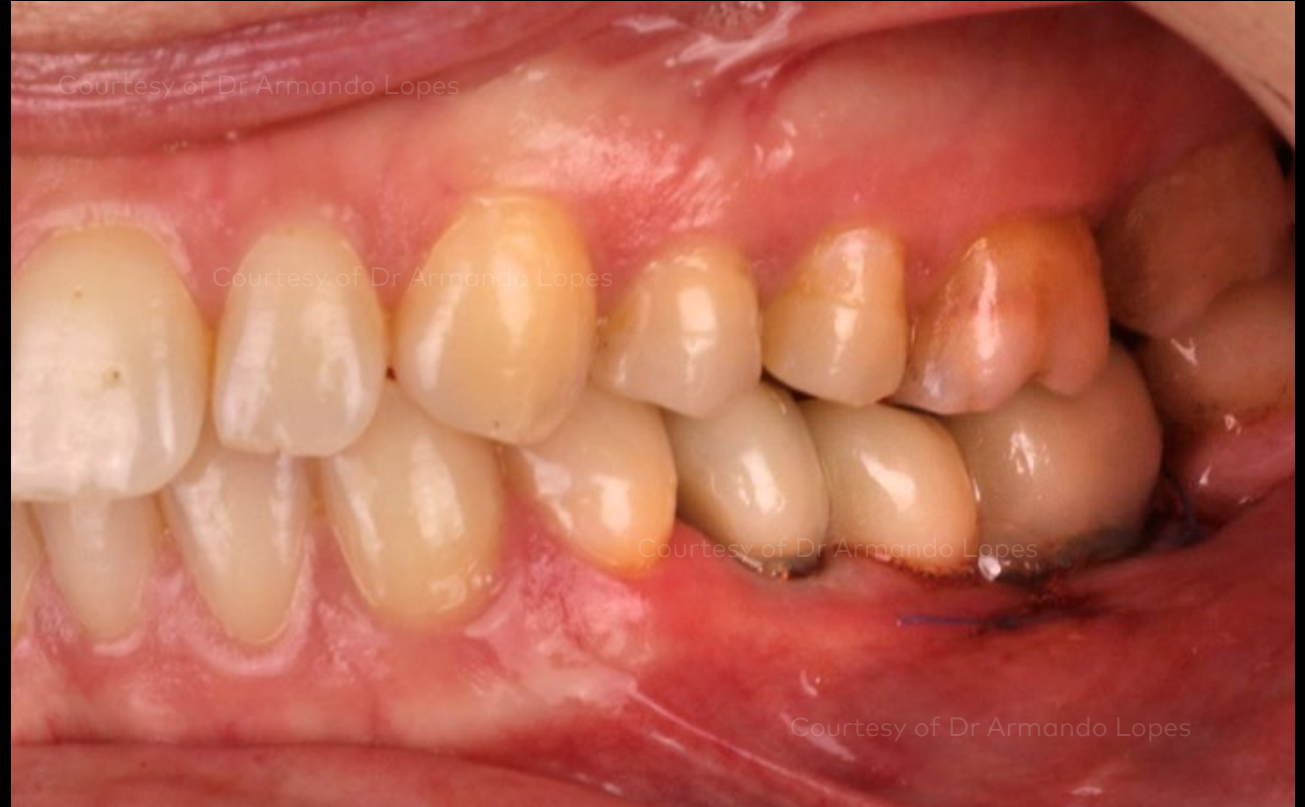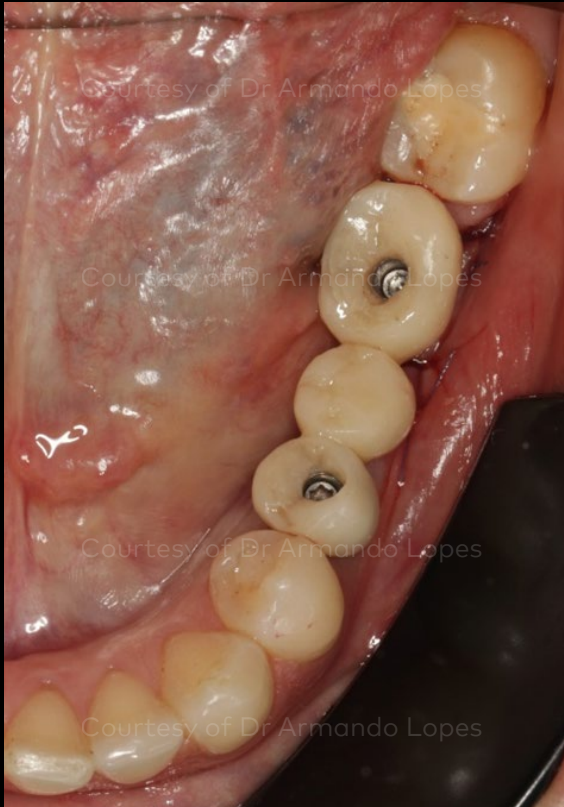The very precise X-Guide navigation allows for implant placement in proximity of buccal wall according to digital planning. NobelParallel CC NP 3.75 x 8.5 mm implant was chosen to fit the prosthetic design.

Initial clinical situation

Treatment planning

Surgical procedure

Outcome



Occlusal view of the provisional bridge immediately following surgery, before covering of the screw access channels.

Lateral view of the provisional bridge.

Initial clinical situation

Treatment planning

Surgical procedure

Outcome

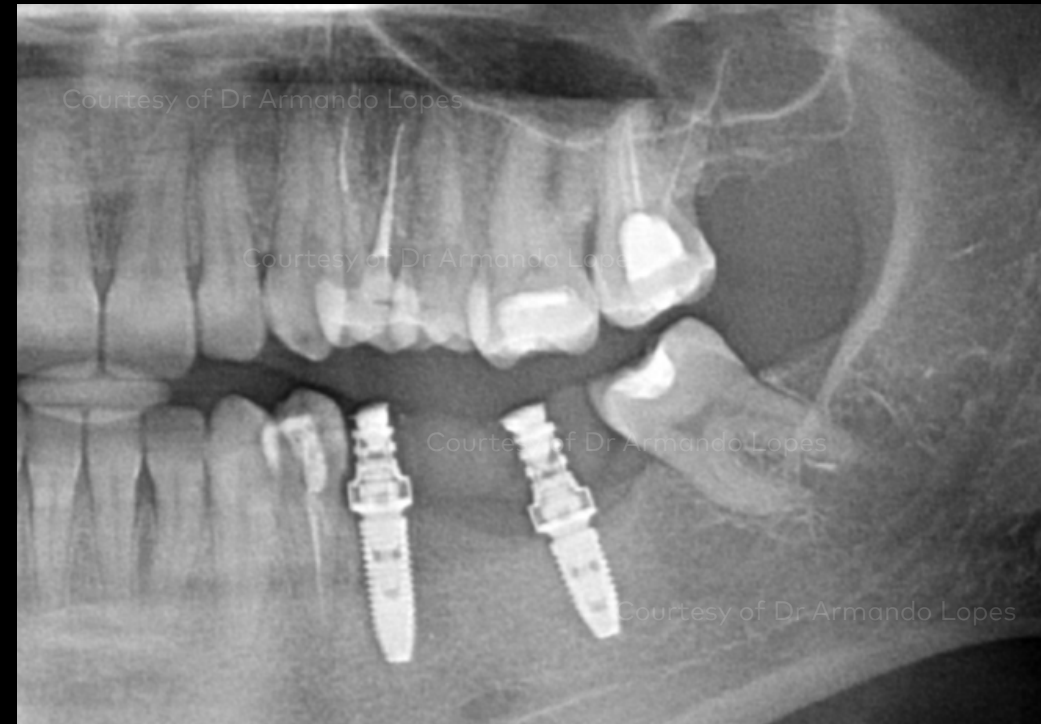Courtesy of Dr Armando Lopes



Courtesy of Dr Armando Lopes

Post-operative extraoral photograph of patient's smile with provisional bridge.

Courtesy of Dr Armando Lopes



Courtesy of Dr Armando Lopes

Courtesy of Dr Armando Lopes

Courtesy of Dr Armando Lopes

OPG of converted TempShell provisional bridge immediately following surgery.

Case courtesy of Armando Lopes

